Vorlesung Klappenerkrankungen

Mitralklappe
Tricuspidalklappe

UniversitätsSpital Zürich

Klappenerkrankungen

Prävalenz

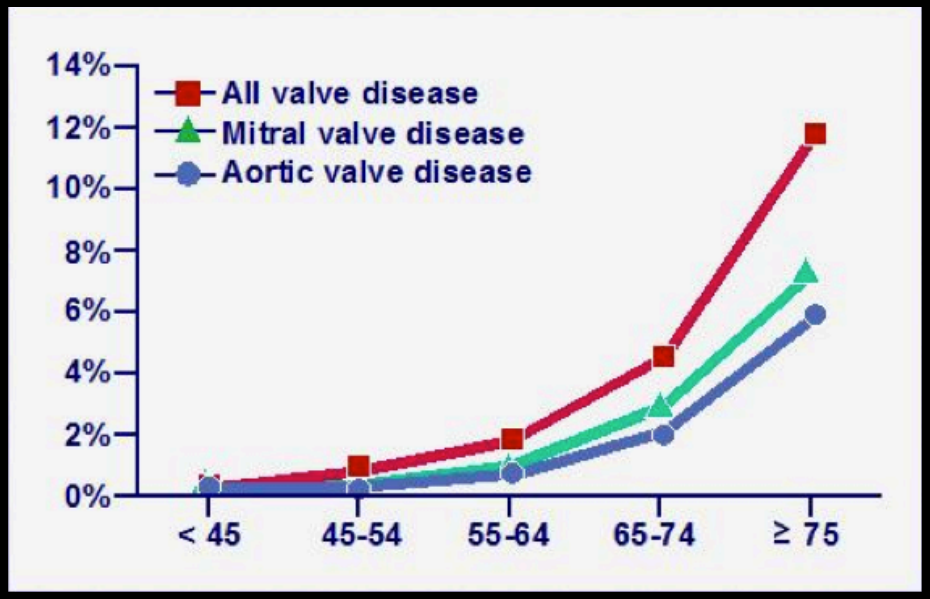

Prognose

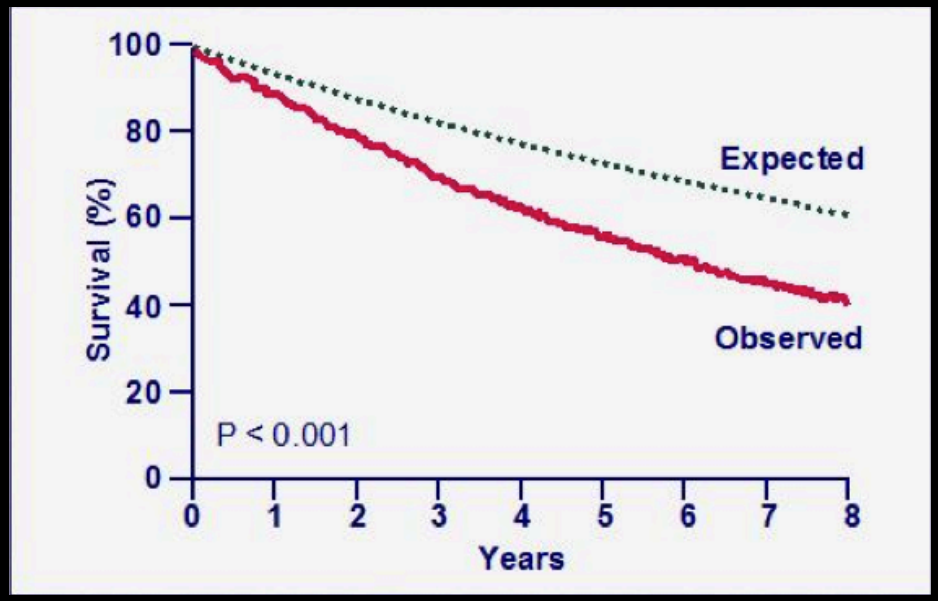

Nkomo et al. Lancet 2006;368:1005-1011

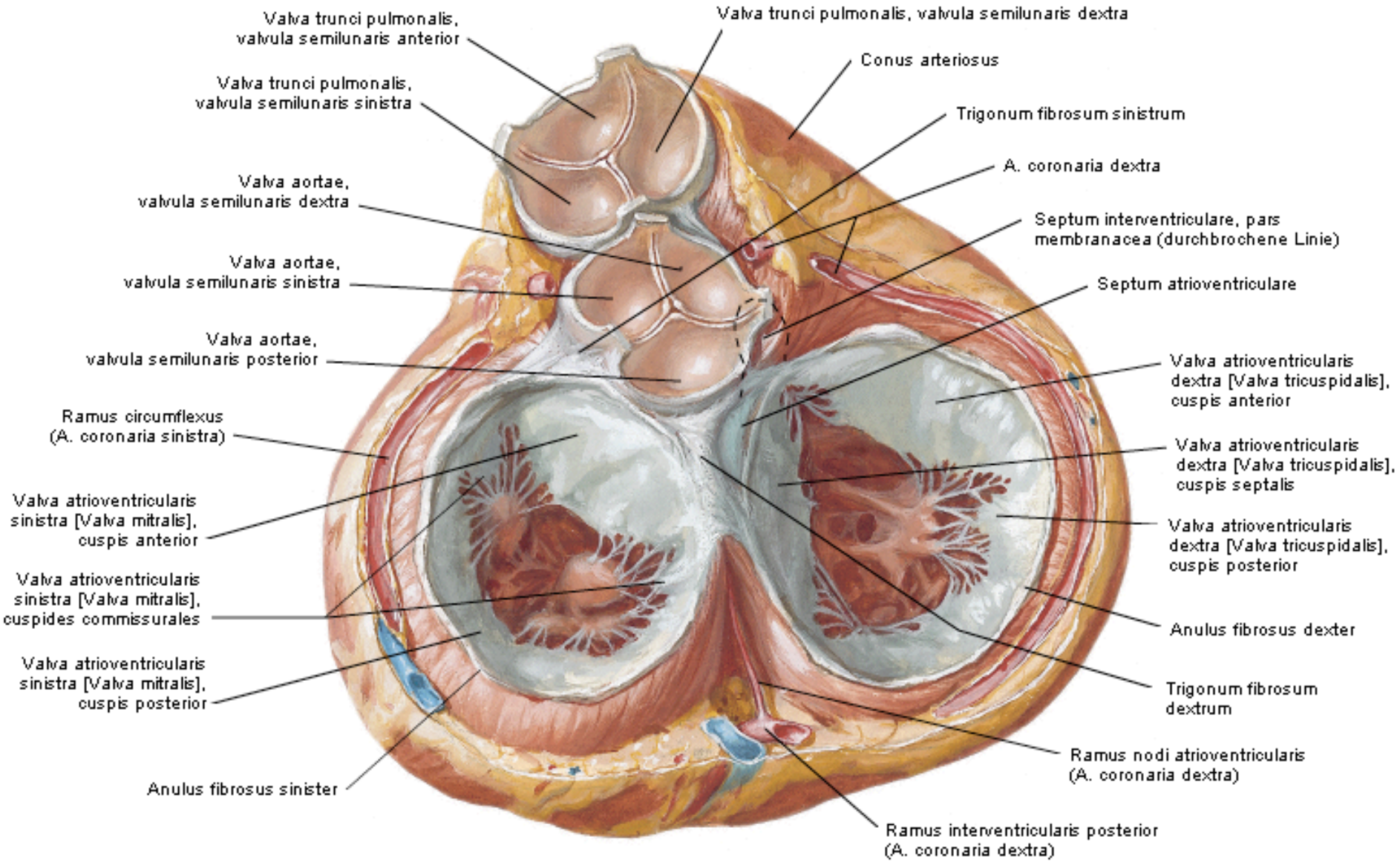
Valva trunci pulmonalis, valvula semilunaris anterior
Valva trunci pulmonalis, valvula semilunaris dextra
Conus arteriosus
Valva trunci pulmonalis, valvula semilunaris sinistra
Trigonum fibrosum sinistrum
A. coronaria dextra
Valva aortae, valvula semilunaris dextra
Septum interventriculare, pars membranacea (durchbrochene Linie)
Valva aortae, valvula semilunaris sinistra
Septum atrioventriculare
Valva aortae, valvula semilunaris posterior
Valva atrioventricularis dextra [Valva tricuspidalis], cuspis anterior
Ramus circumflexus (A. coronaria sinistra)
Valva atrioventricularis dextra [Valva tricuspidalis], cuspis septalis
Valva atrioventricularis sinistra [Valva mitralis], cuspis anterior
Valva atrioventricularis dextra [Valva tricuspidalis], cuspis posterior
Valva atrioventricularis sinistra [Valva mitralis], cuspides commissurales
Anulus fibrosus dexter
Valva atrioventricularis sinistra [Valva mitralis], cuspis posterior
Trigonum fibrosum dextrum
Ramus nodi atrioventricularis (A. coronaria dextra)
Anulus fibrosus sinister
Ramus interventricularis posterior (A. coronaria dextra)

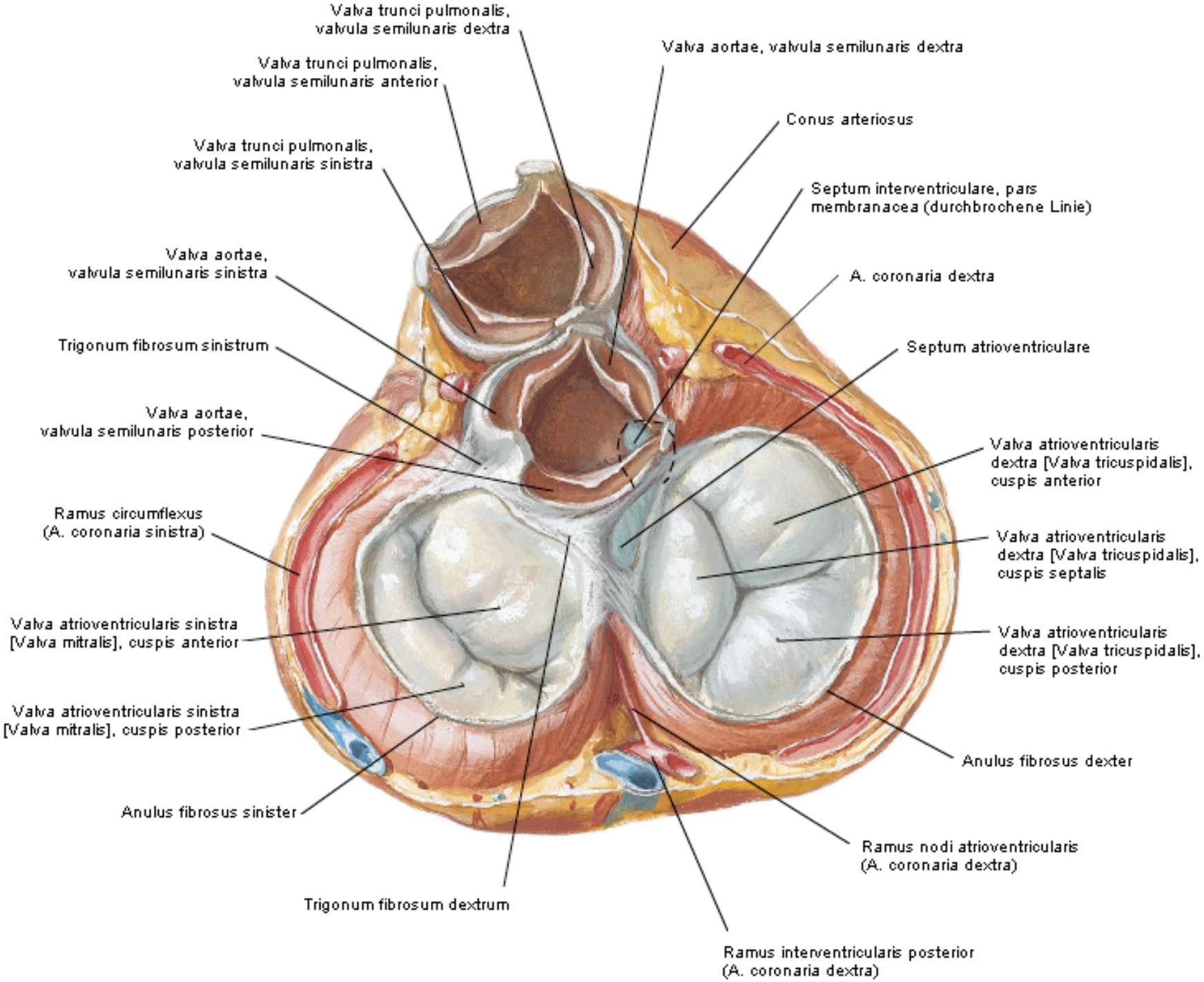
Valva trunci pulmonalis, valvula semilunaris dextra
Valva aortae, valvula semilunaris dextra
Valva trunci pulmonalis, valvula semilunaris anterior
Conus arteriosus
Valva trunci pulmonalis, valvula semilunaris sinistra
Septum interventriculare, pars membranacea (durchbrochene Linie)
Valva aortae, valvula semilunaris sinistra
A. coronaria dextra
Trigonum fibrosum sinistrum
Septum atrioventriculare
Valva aortae, valvula semilunaris posterior
Valva atrioventricularis dextra [Valva tricuspidalis], cuspis anterior
Ramus circumflexus (A. coronaria sinistra)
Valva atrioventricularis dextra [Valva tricuspidalis], cuspis septalis
Valva atrioventricularis sinistra [Valva mitralis], cuspis anterior
Valva atrioventricularis dextra [Valva tricuspidalis], cuspis posterior
Valva atrioventricularis sinistra [Valva mitralis], cuspis posterior
Anulus fibrosus dexter
Anulus fibrosus sinister
Ramus nodi atrioventricularis (A. coronaria dextra)
Trigonum fibrosum dextrum
Ramus interventricularis posterior (A. coronaria dextra)

Mitralklappenerkrankungen

Mitralinsuffizienz

Mitralstenose

Ursachen der Mitralinsuffizienz

Verteilung der Ursachen nach Alter

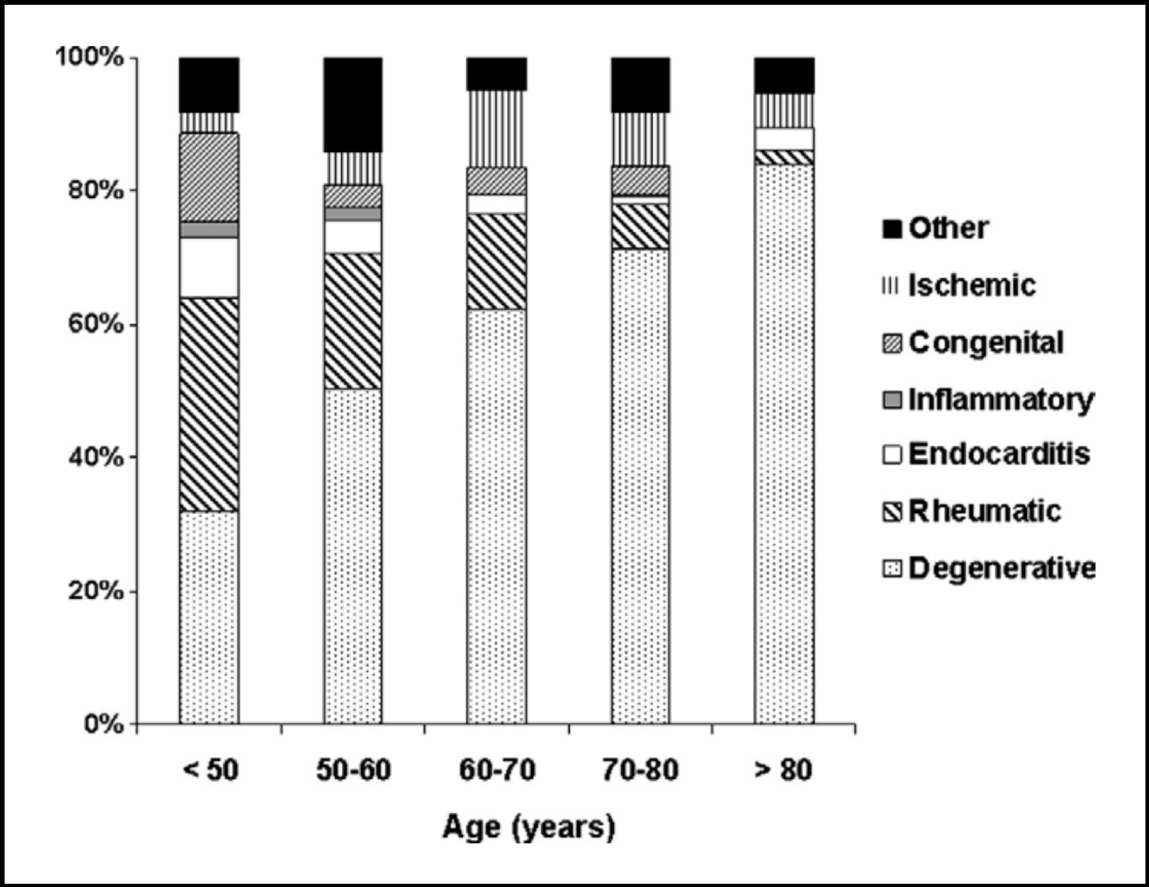

Iung et al. Curr Probl Cardiol 2007;32:609-661

Mitralklappe: Anatomie

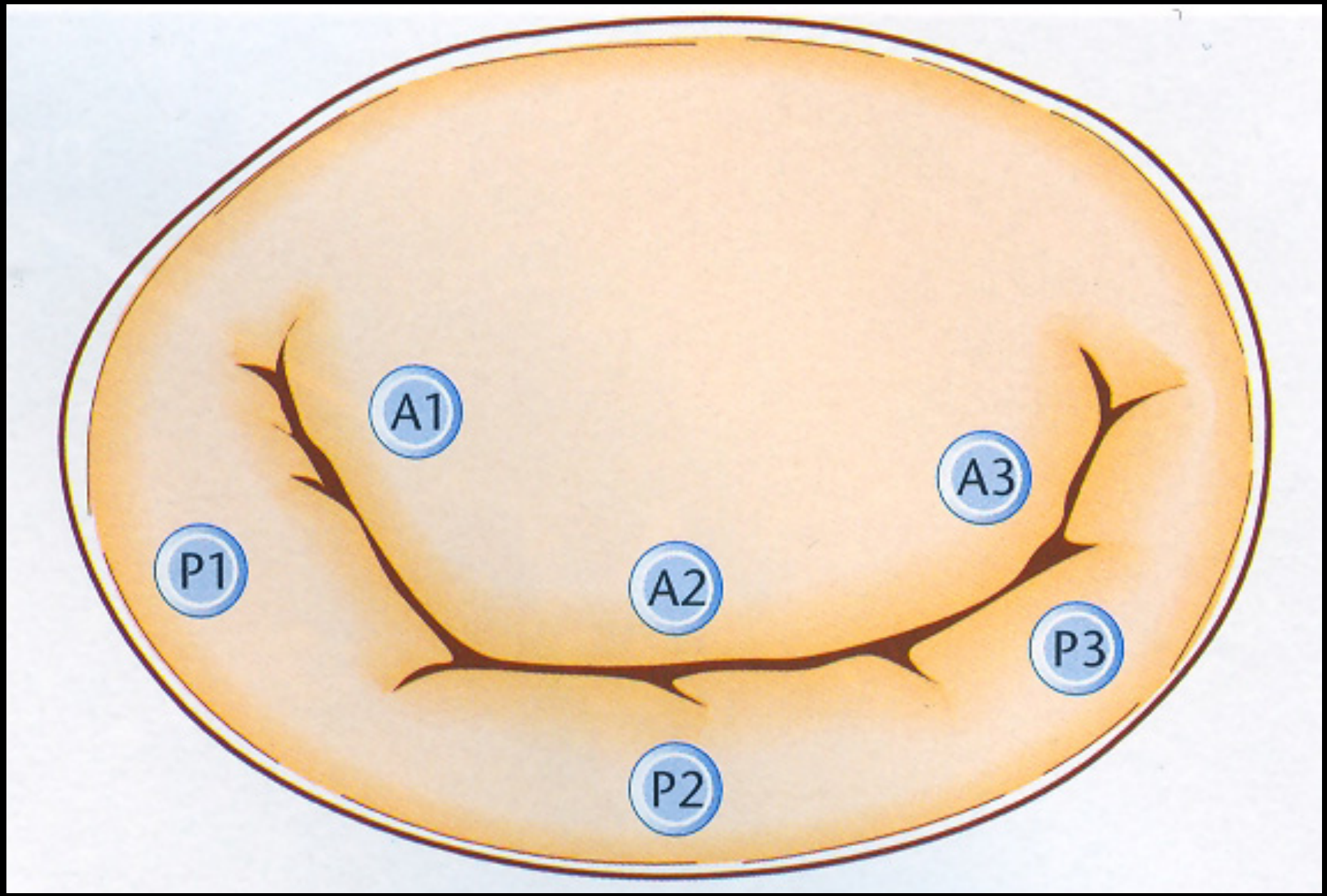

Echokardiographie bei Mitralklappenerkrankungen

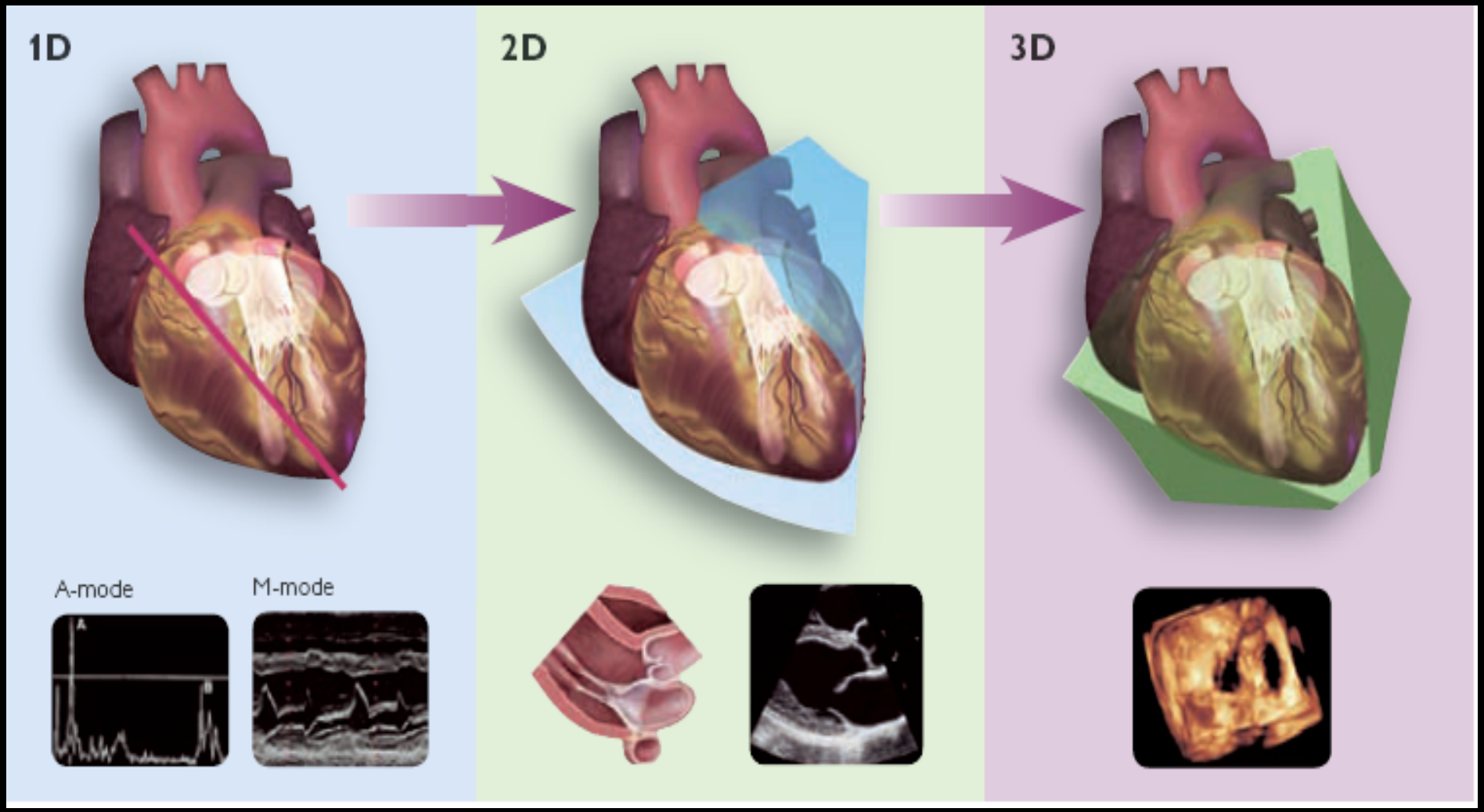

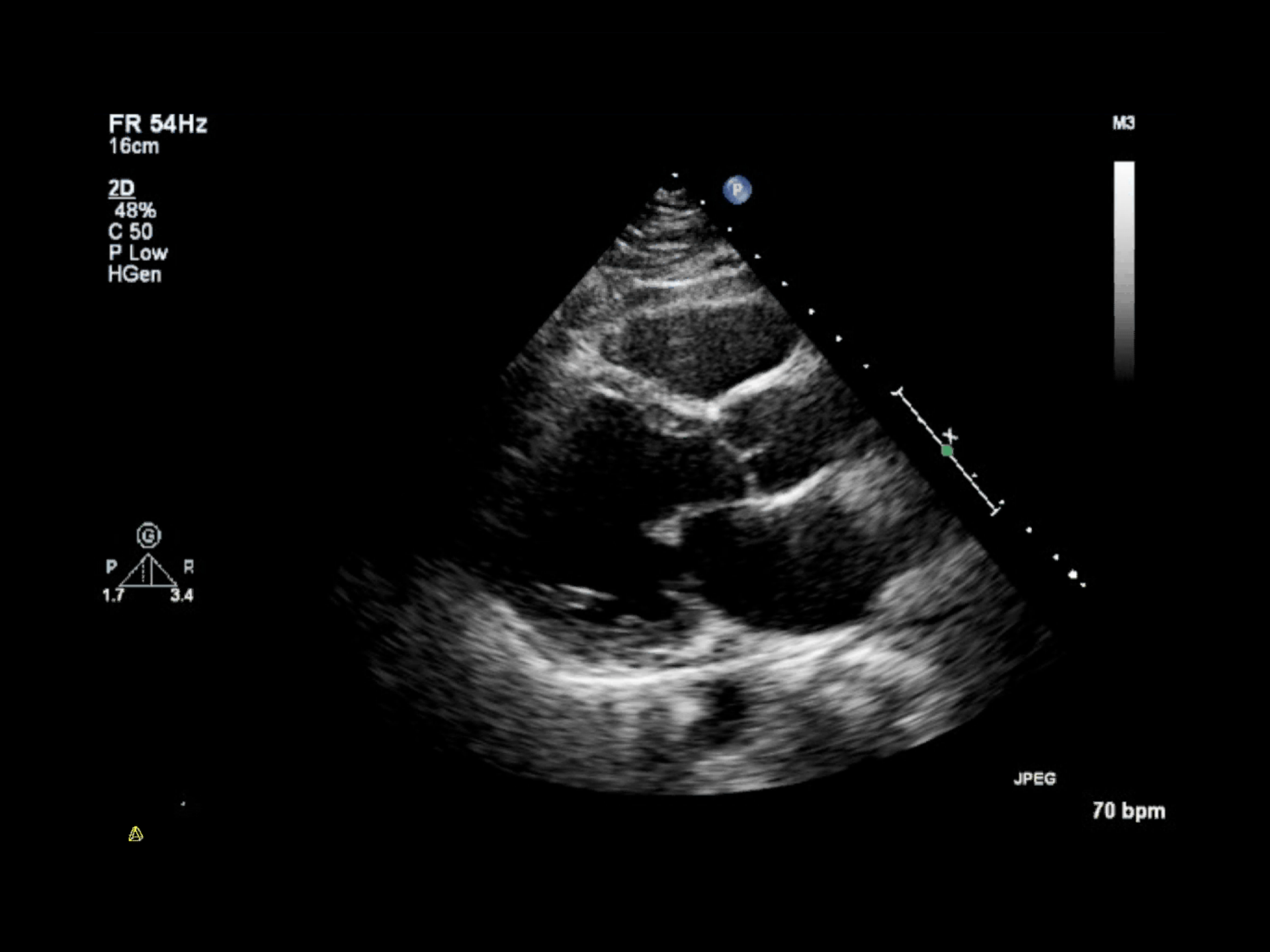
FR 54Hz
16cm
2D
48%
C 50
P Low
HGen
M3
P
G
P
R
1.7
3.4
JPEG
70 bpm

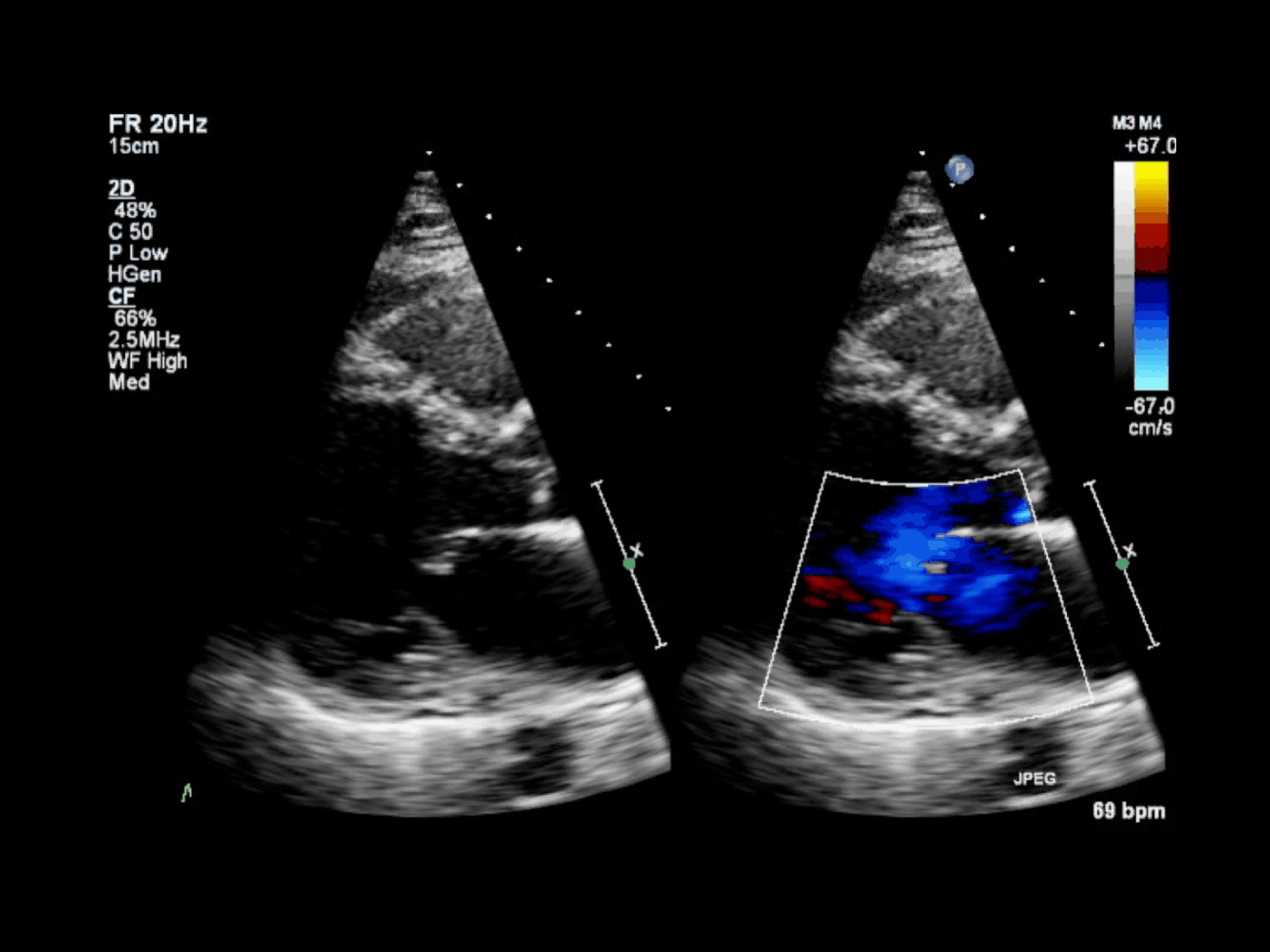
FR 20Hz
15cm
2D
48%
C 50
P Low
HGen
CF
66%
2.5MHz
WF High
Med
M3 M4
+67.0
-67.0
cm/s
JPEG
69 bpm

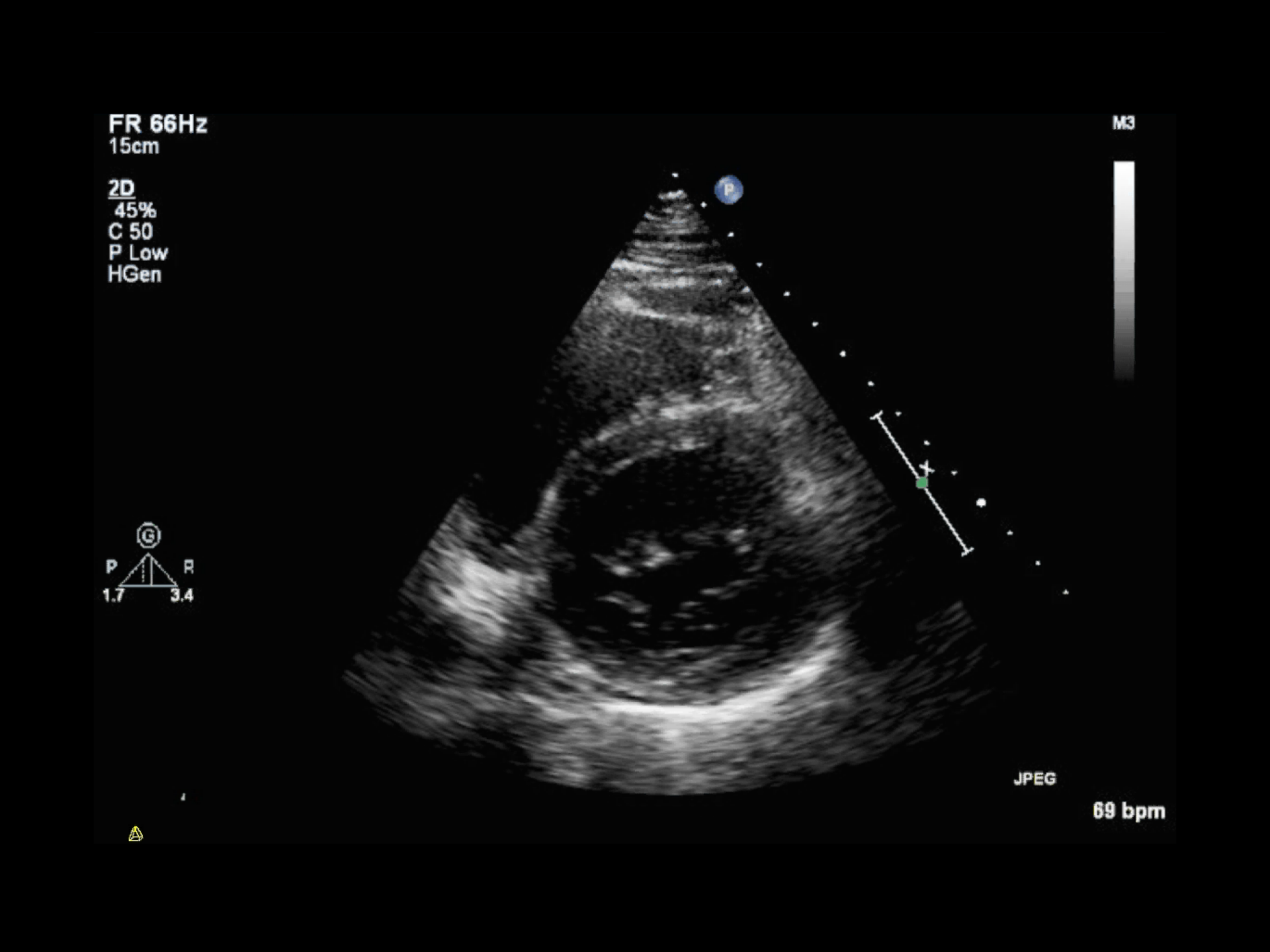
FR 66Hz
15cm
2D
45%
C 50
P Low
HGen
M3
P
G
P
R
1.7
3.4
JPEG
69 bpm

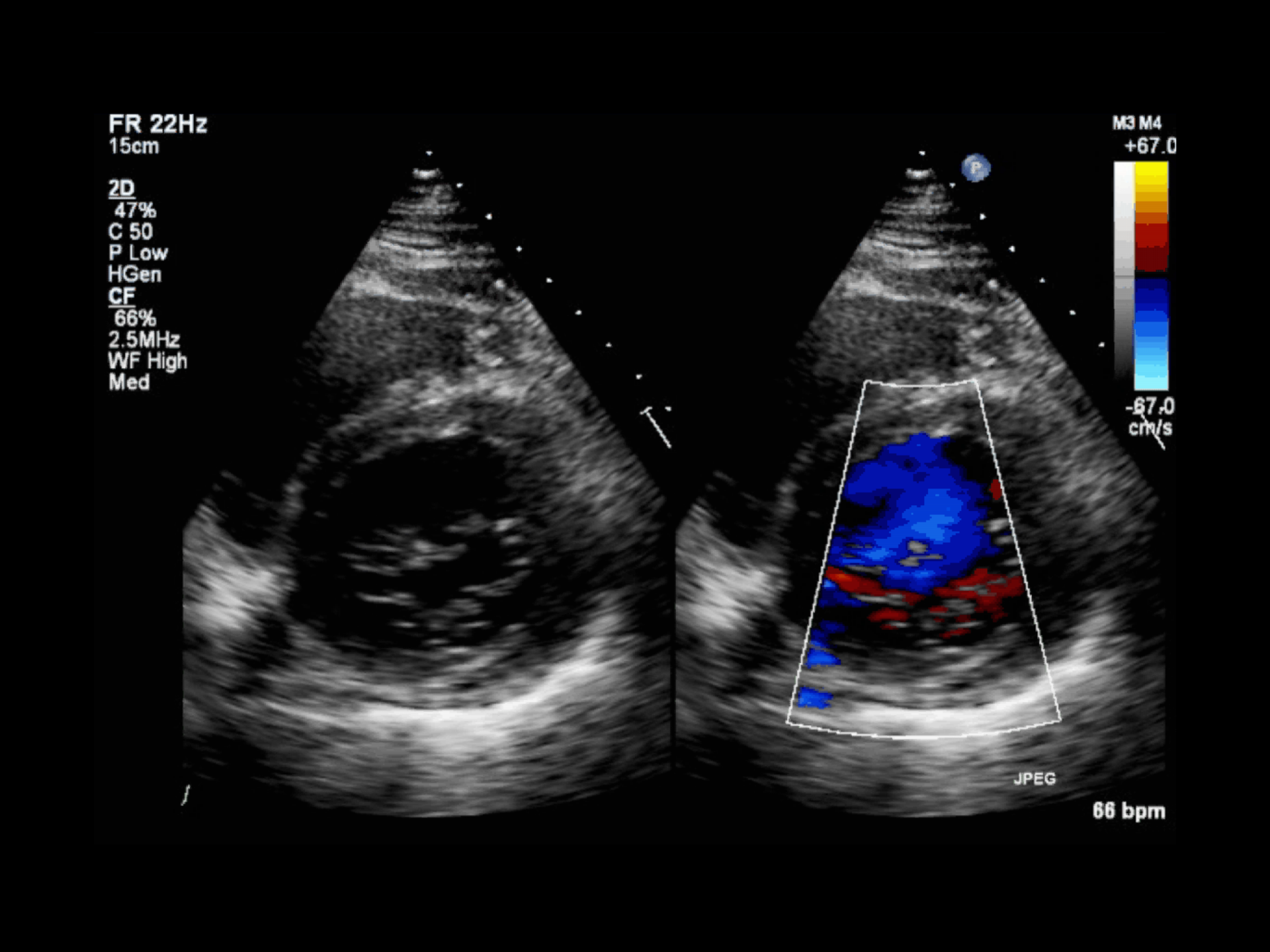
FR 22Hz
15cm
2D
47%
C 50
P Low
HGen
CF
66%
2.5MHz
WF High
Med
M3 M4
+67.0
-67.0
cm/s
JPEG
66 bpm

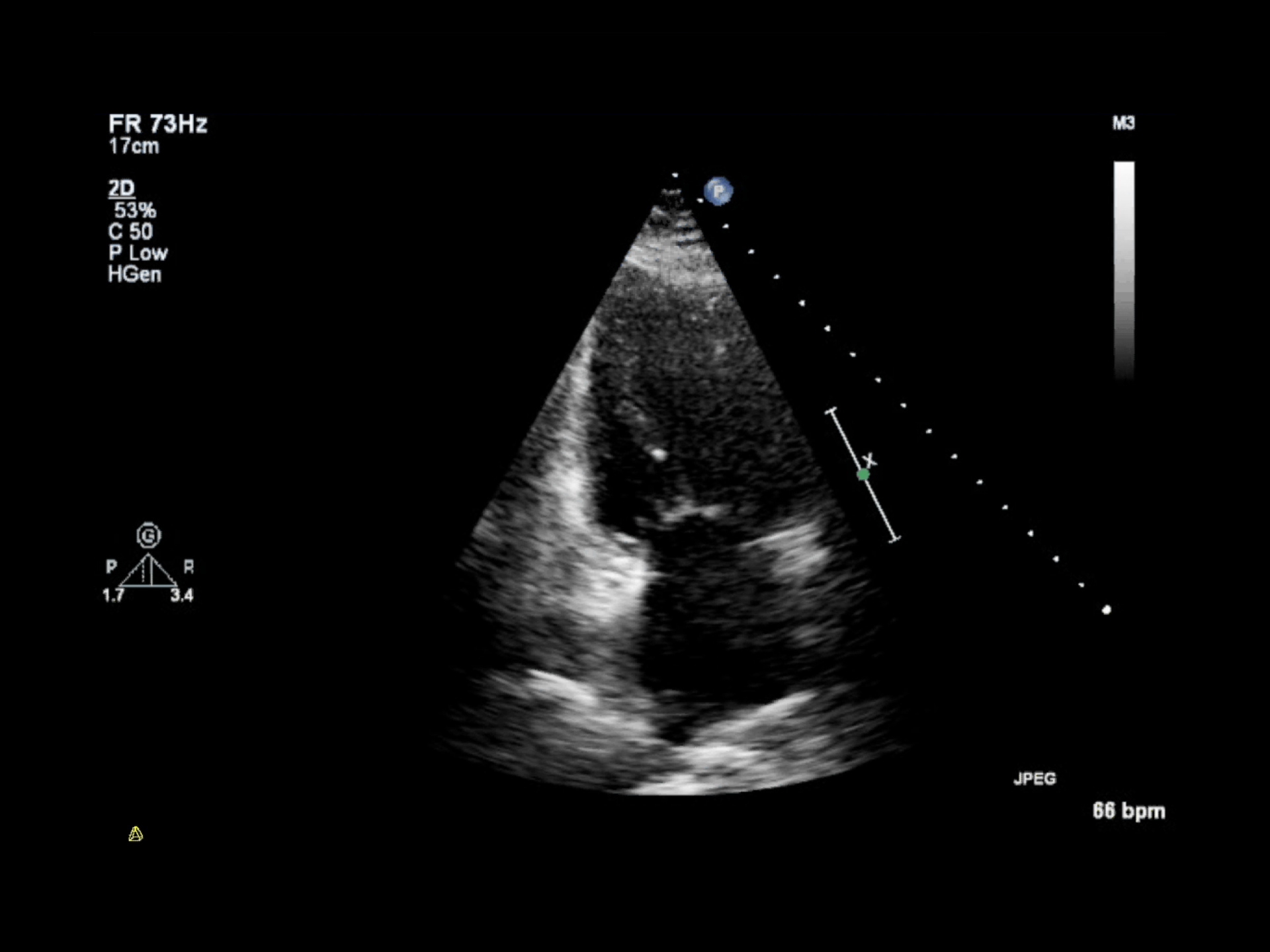
FR 73Hz
17cm
2D
53%
C 50
P Low
HGen
M3
P
R
1.7
3.4
JPEG
66 bpm

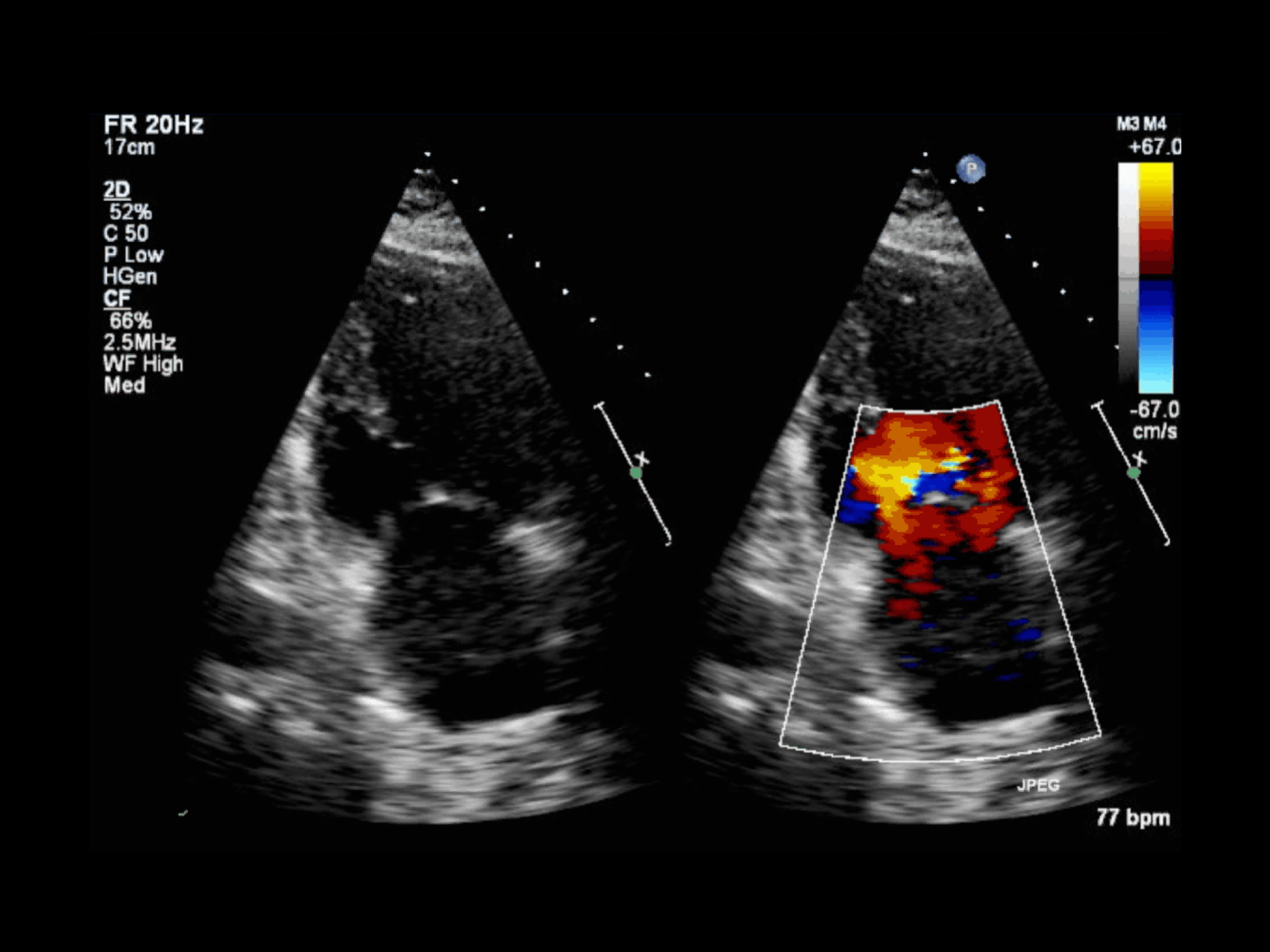
FR 20Hz
17cm
2D
52%
C 50
P Low
HGen
CF
66%
2.5MHz
WF High
Med
M3 M4
+67.0
-67.0
cm/s
P
JPEG
77 bpm

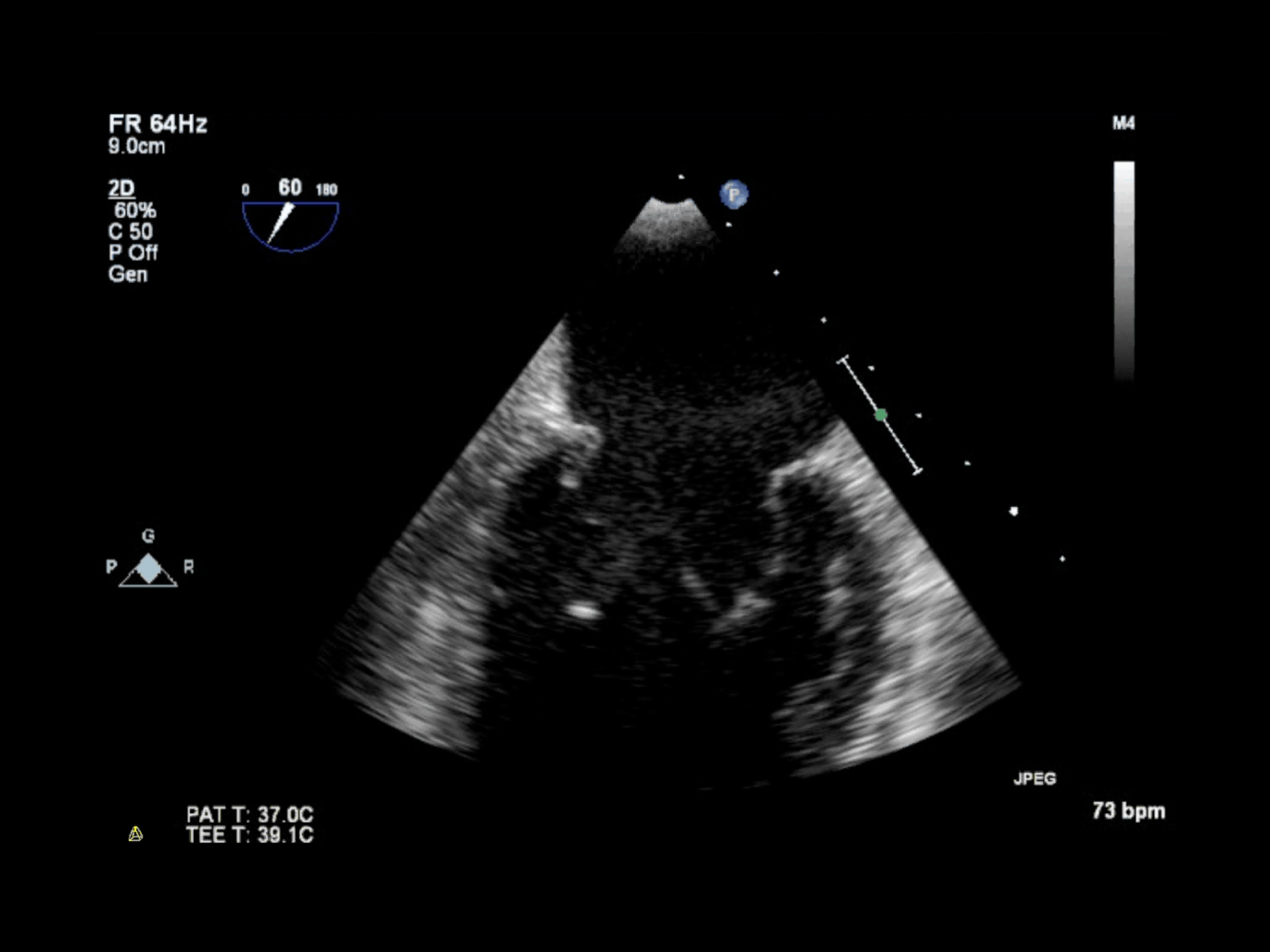
FR 64Hz
9.0cm
2D
60%
C 50
P Off
Gen
0
60
180
M4
P
G
P
R
JPEG
PAT T: 37.0C
TEE T: 39.1C
73 bpm

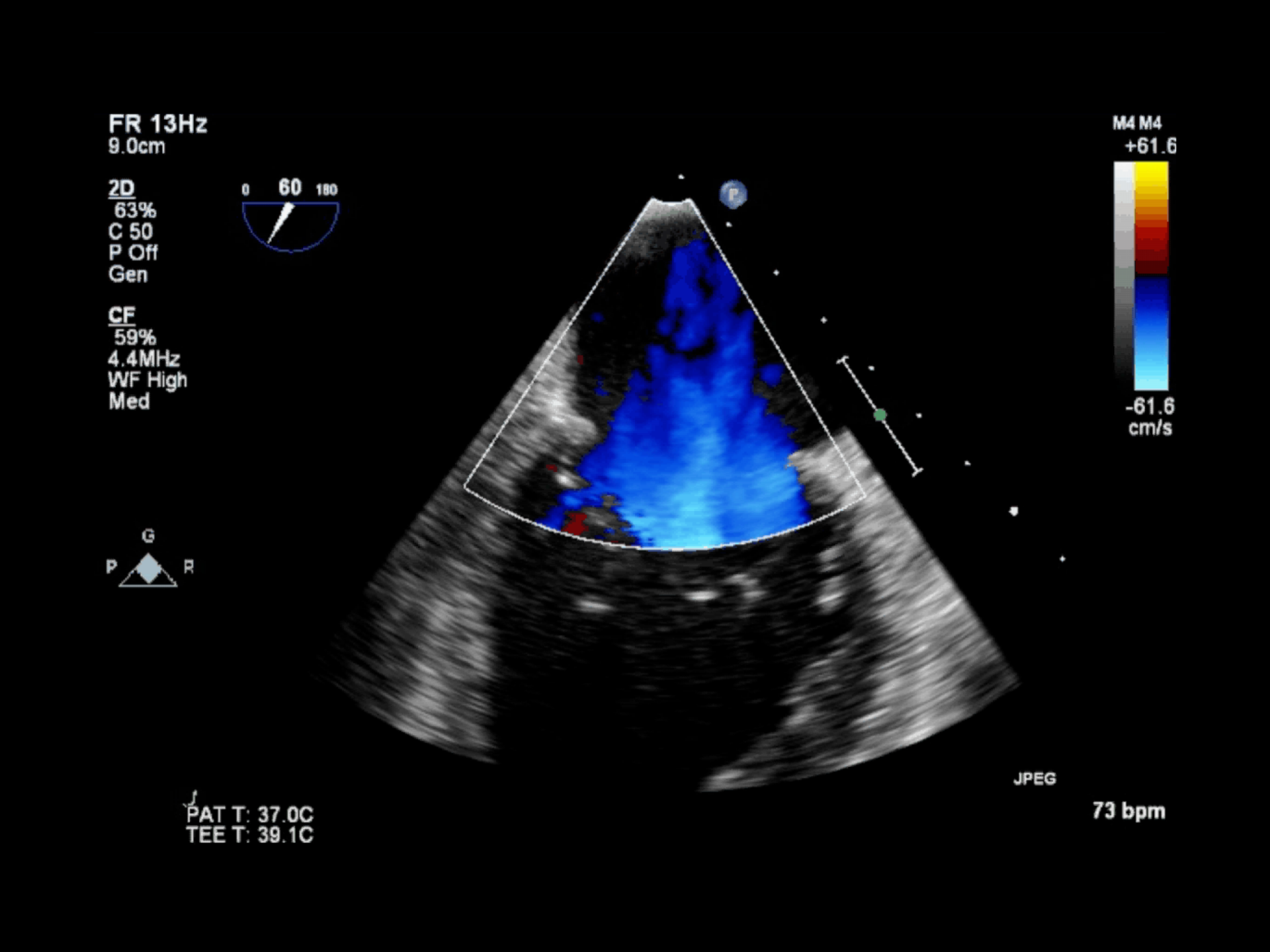
FR 13Hz
9.0cm
2D
63%
C 50
P Off
Gen
CF
59%
4.4MHz
WF High
Med
0
60
180
G
P
R
M4 M4
+61.6
-61.6
cm/s
JPEG
PAT T: 37.0C
TEE T: 39.1C
73 bpm

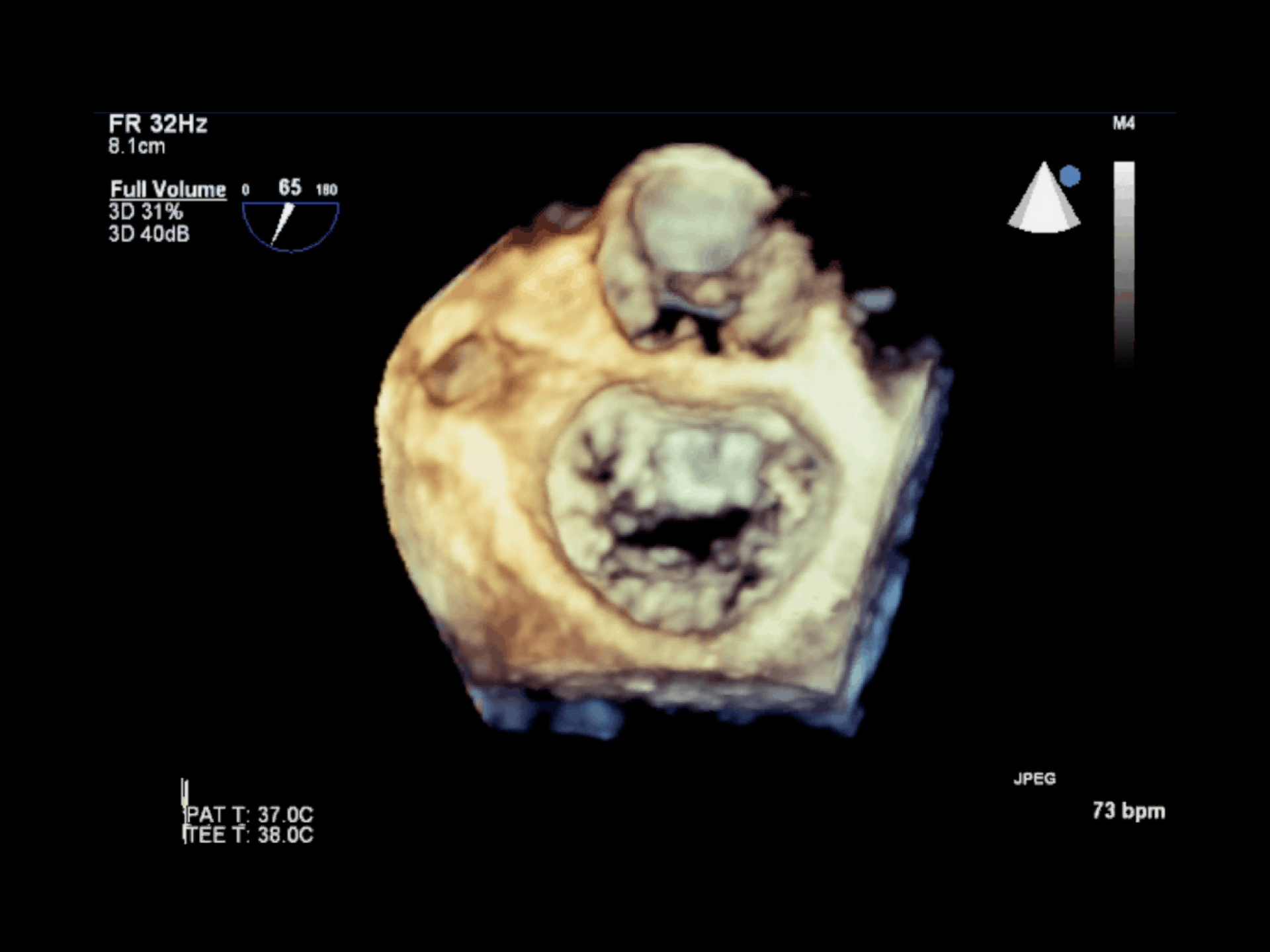
FR 32Hz
8.1cm
Full Volume
3D 31%
3D 40dB
0
65
180
M4
JPEG
73 bpm
PAT T: 37.0C
TEE T: 38.0C

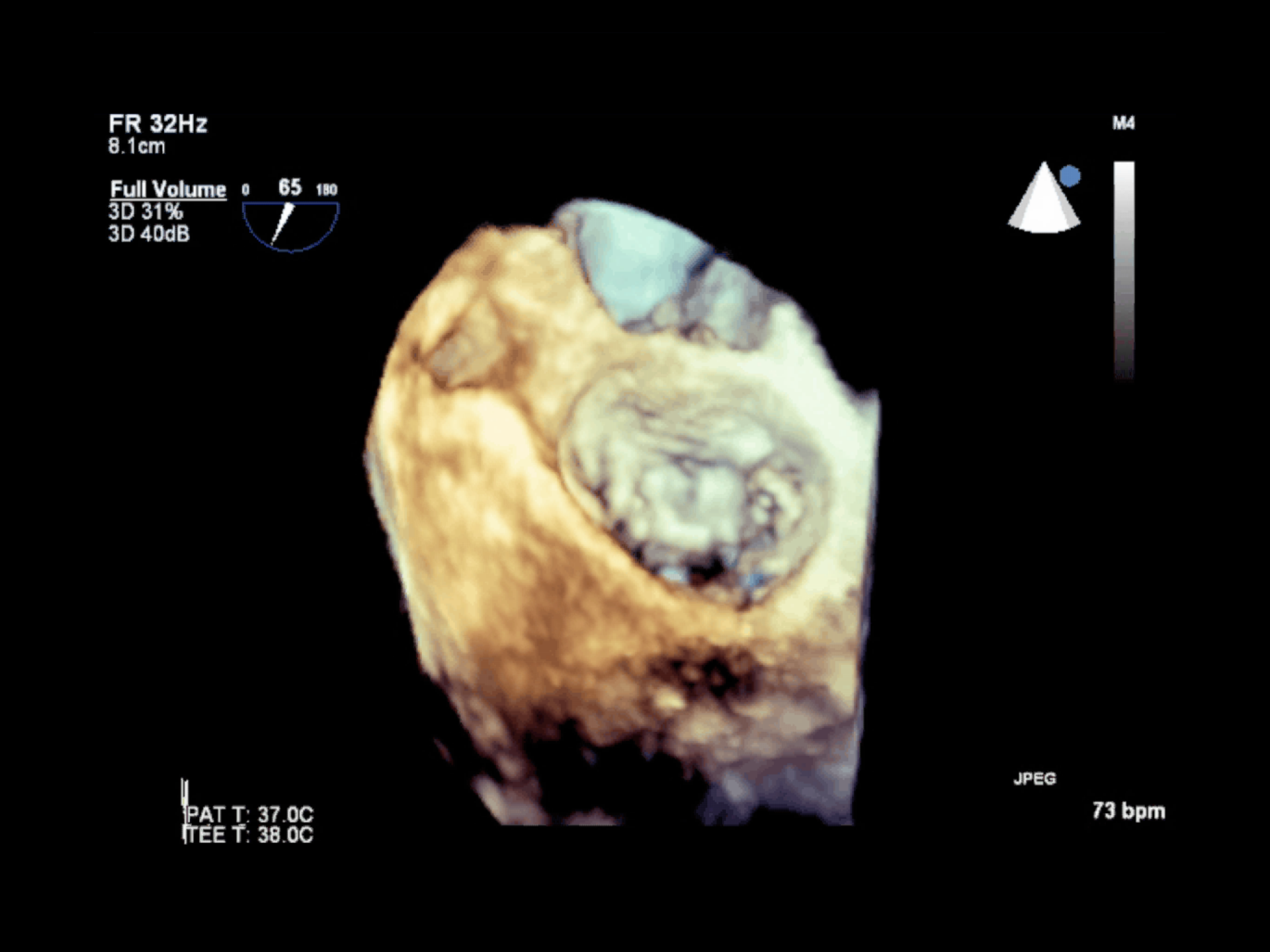
FR 32Hz
8.1cm
Full Volume
3D 31%
3D 40dB
0
65
180
M4
JPEG
73 bpm
PAT T: 37.0C
TEE T: 38.0C

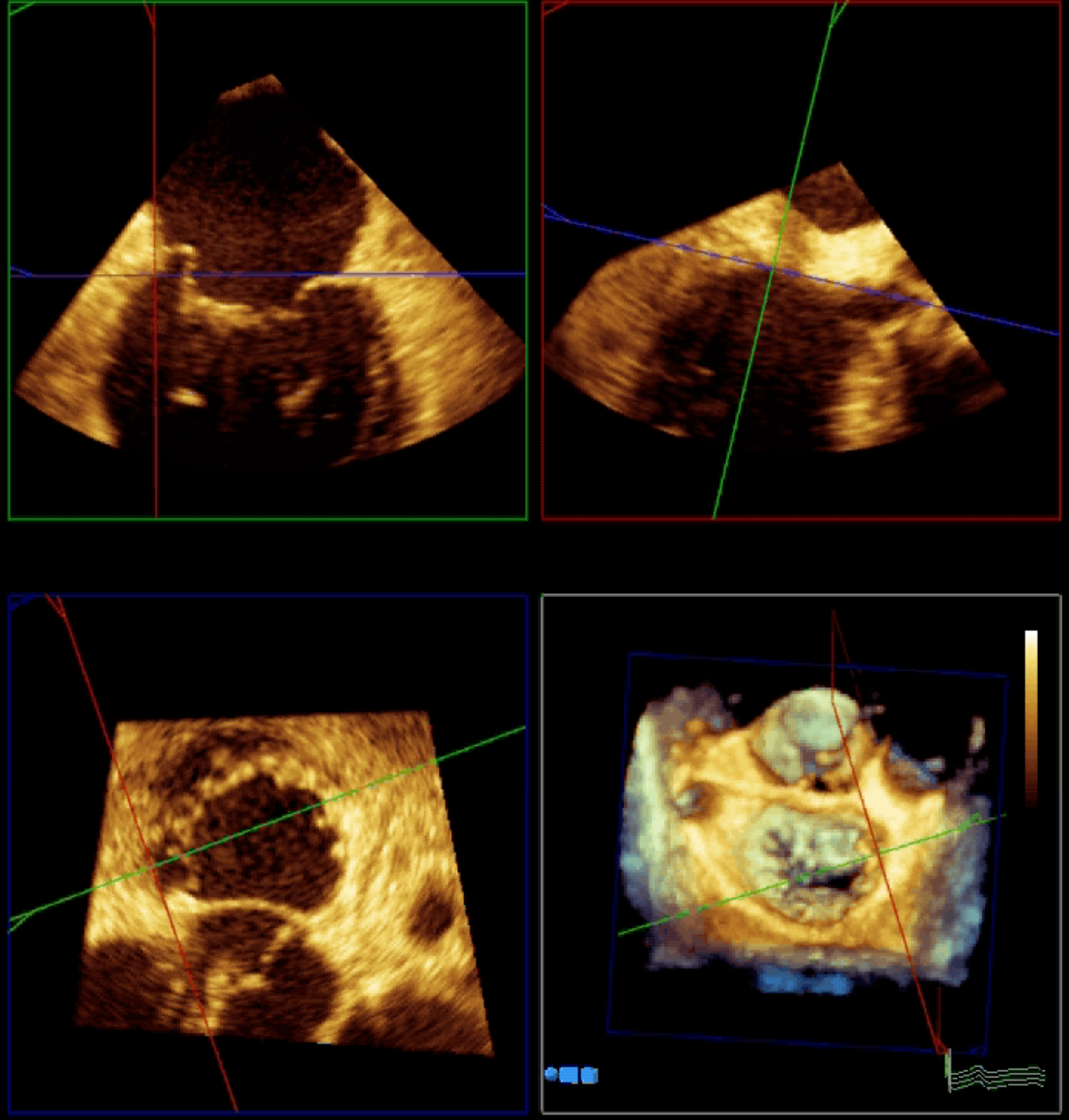

PHILIPS

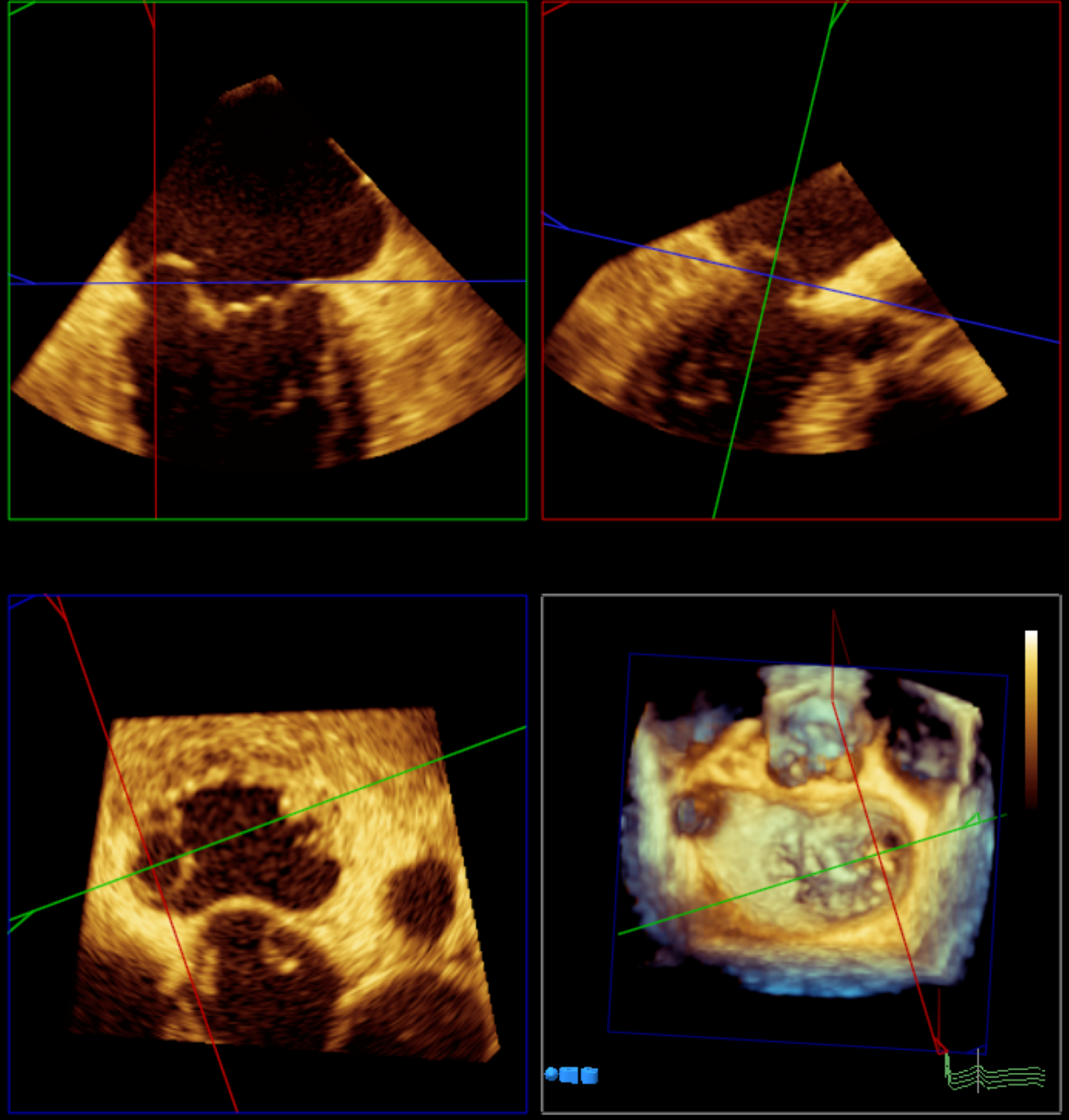

PHILIPS

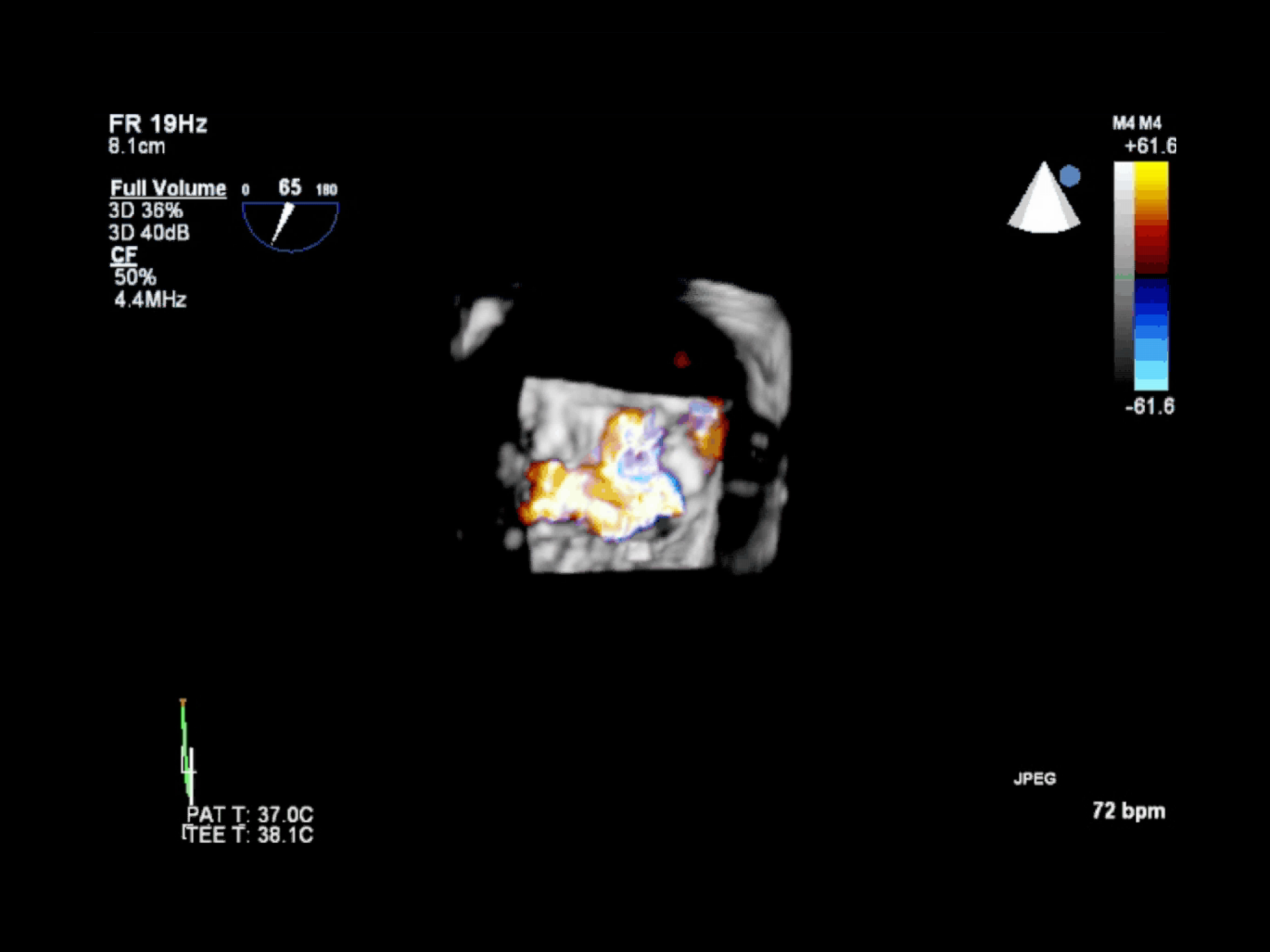
FR 19Hz
8.1cm
Full Volume
3D 36%
3D 40dB
CF
50%
4.4MHz
0
65
180
M4 M4
+61.6
-61.6
PAT T: 37.0C
TEE T: 38.1C
JPEG
72 bpm

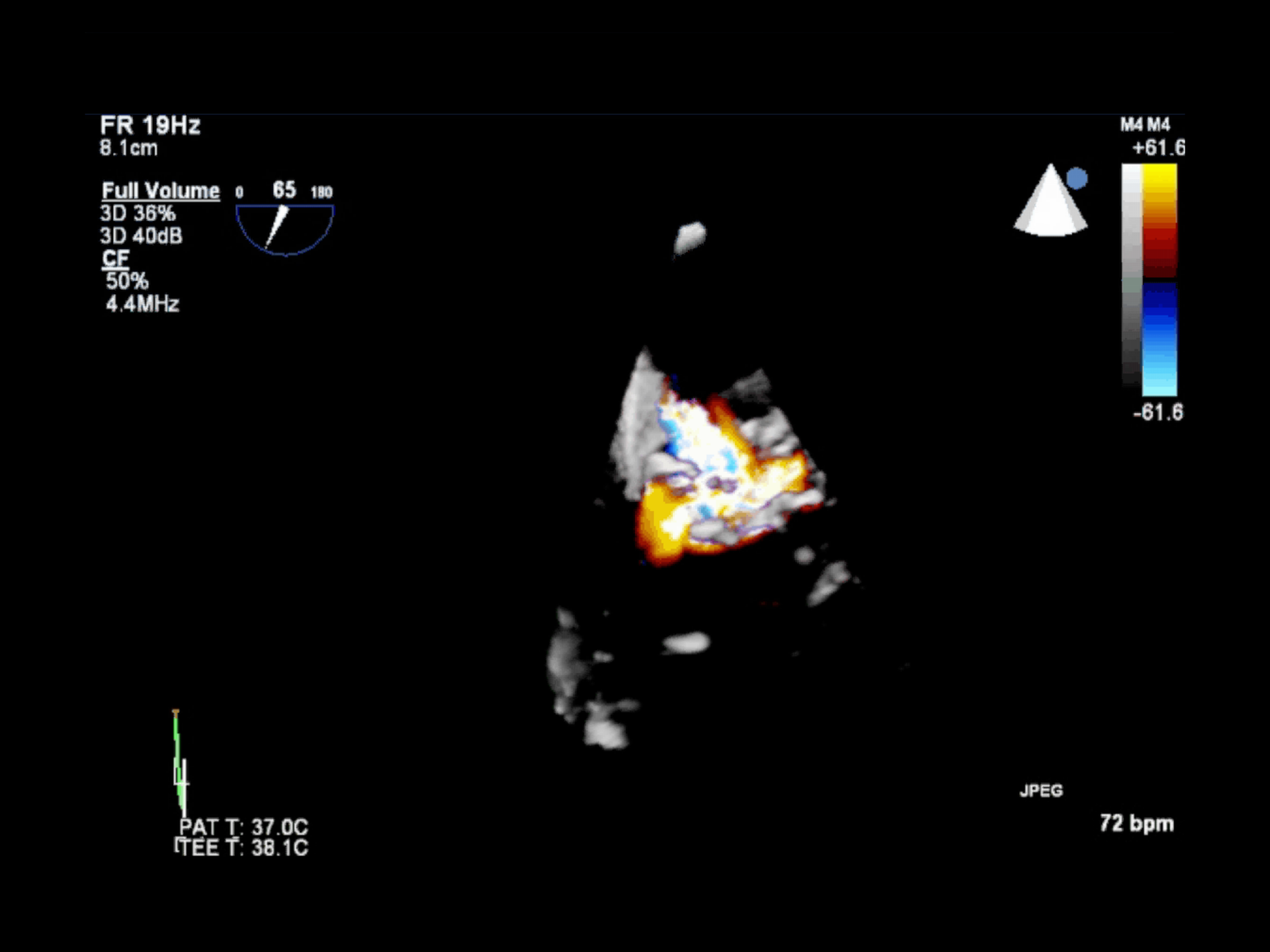
FR 19Hz
8.1cm
Full Volume
3D 36%
3D 40dB
CF
50%
4.4MHz
0
65
180
M4 M4
+61.6
-61.6
PAT T: 37.0C
TEE T: 38.1C
JPEG
72 bpm

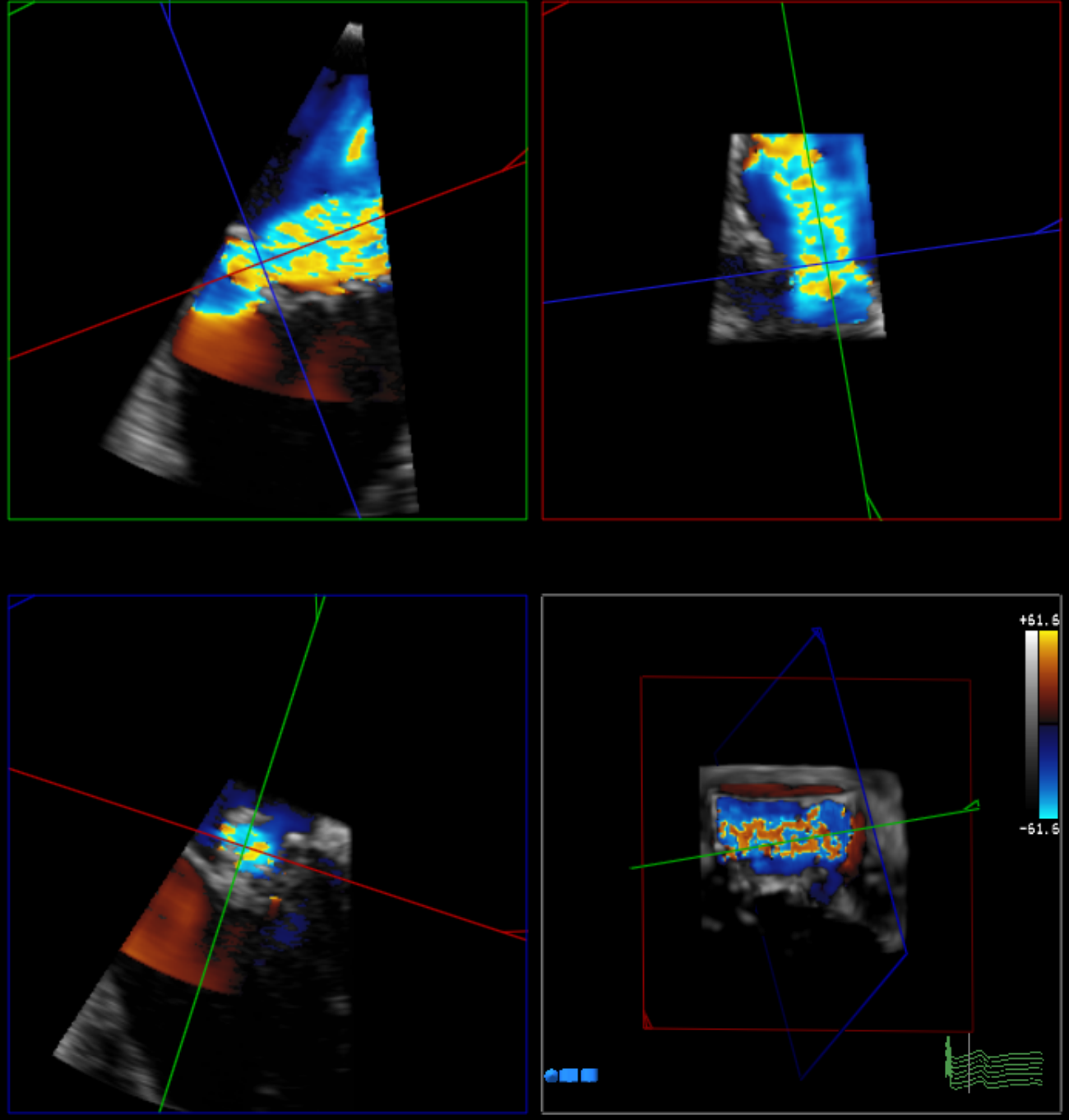

PHILIPS

Hämodynamik der Mitralinsuffizienz

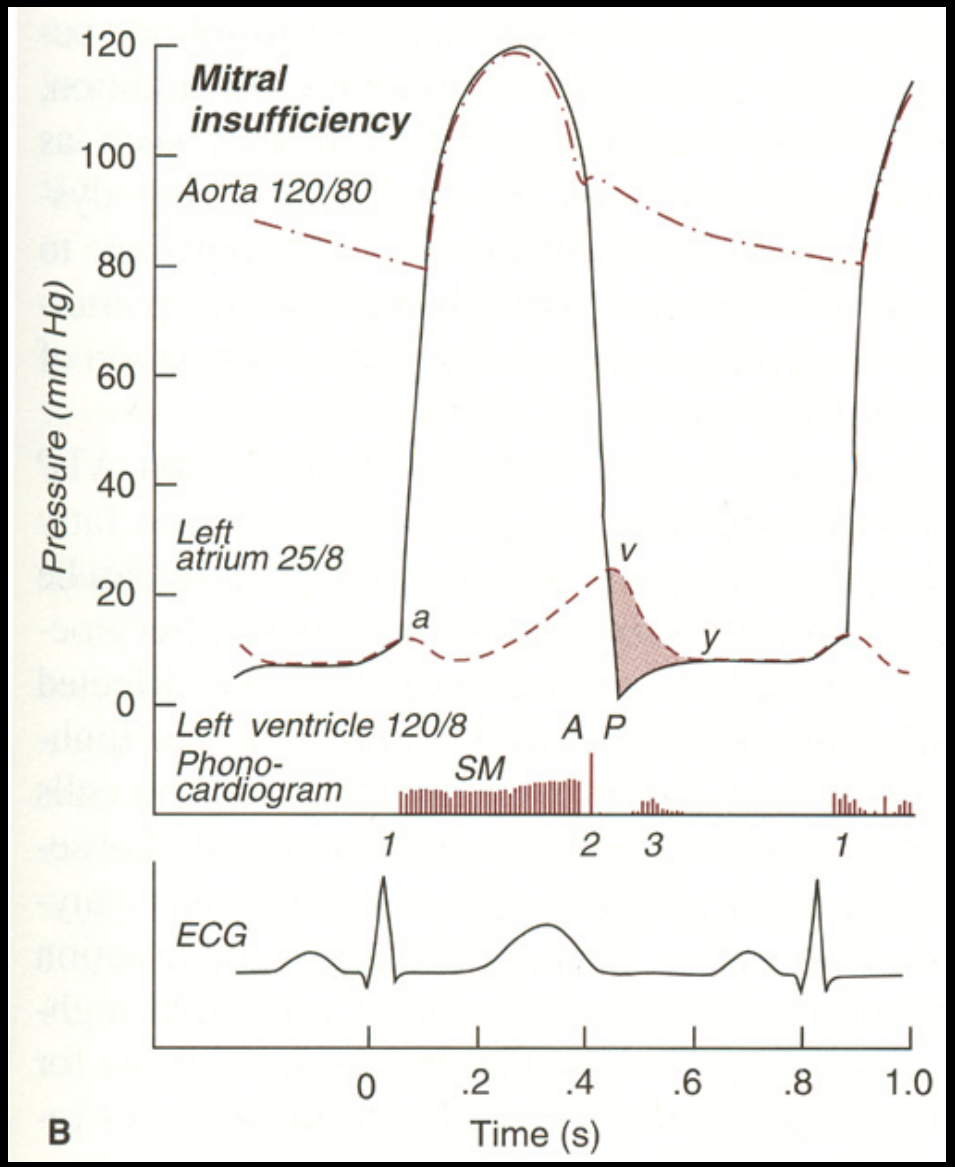

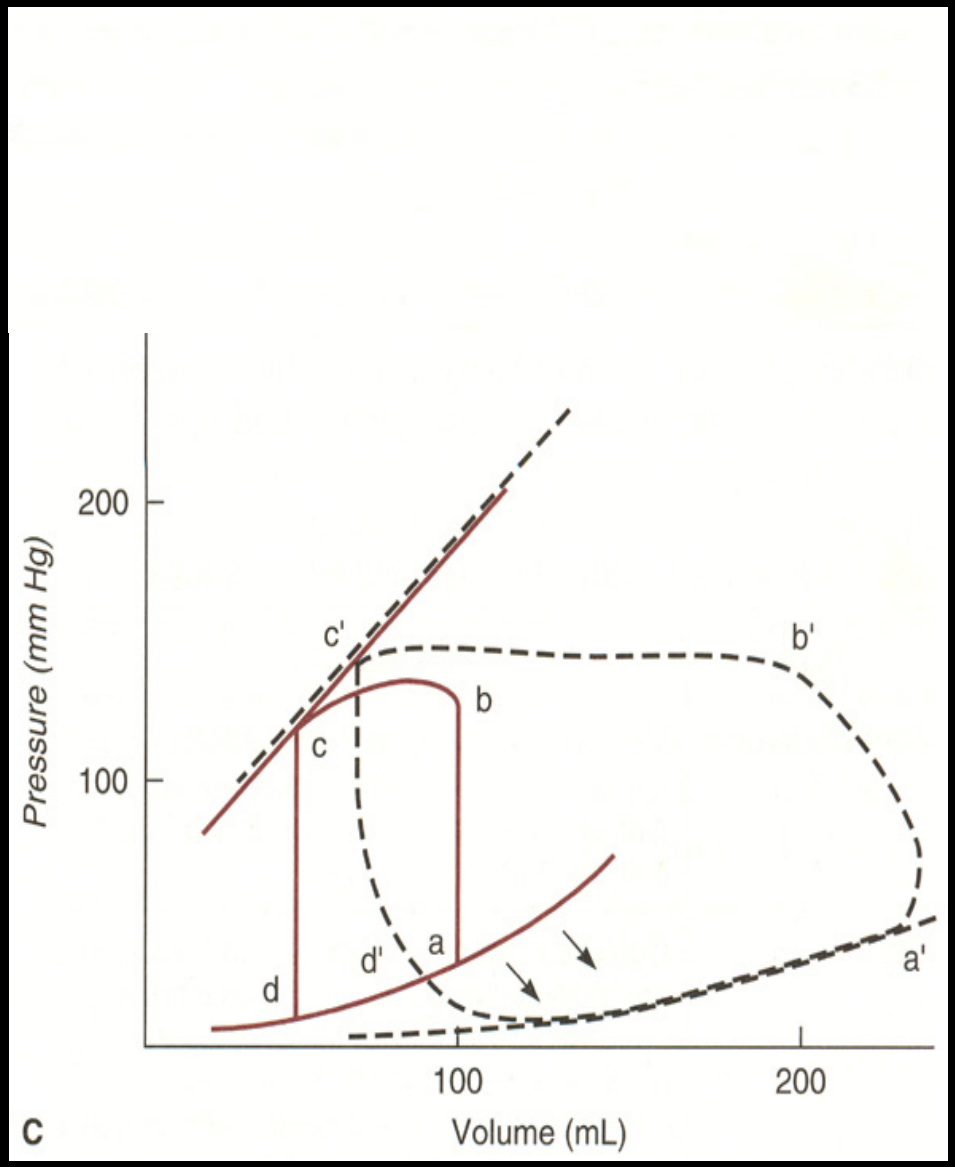

Folgen der Mitralinsuffizienz

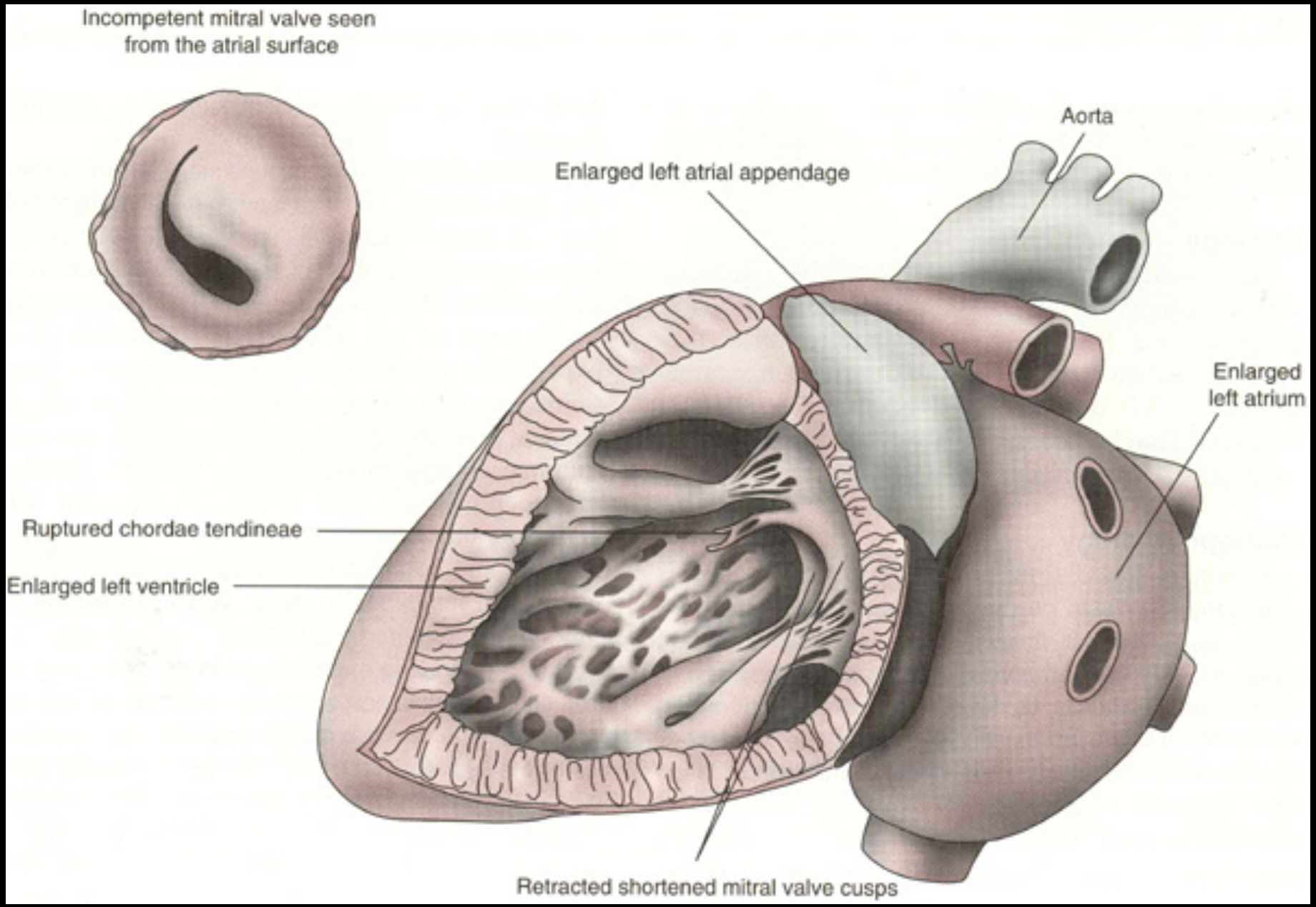

Mitralinsuffizienz und kardiale Funktion

Linker Ventrikel:

Volumenüberlastung
Progressive Dilatation
Myokardiale Hypertrophie
Systolische Dysfunction
Ventrikuläre Arrhythmien

Linker Vorhof:

Progressive Dilatation
Atriale Arrhythmien
Atriale Thromben

Sekundäre pulmonale Hypertonie

Mitralinsuffizienz

Untersuchung von Patienten mit MI

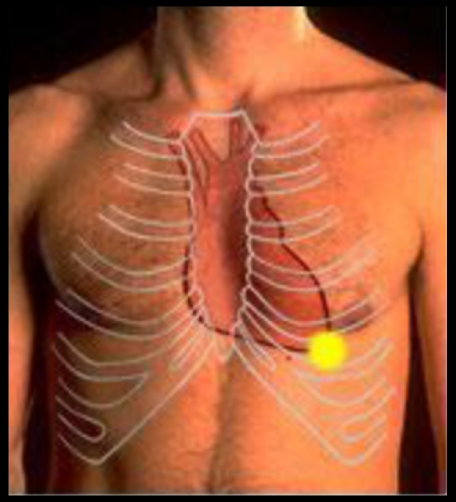

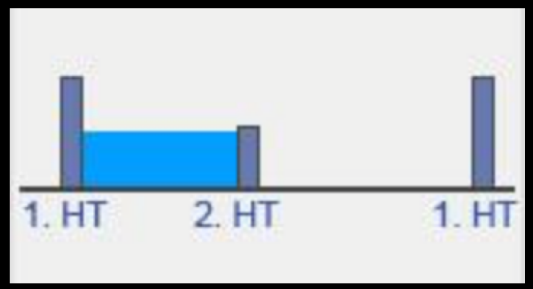

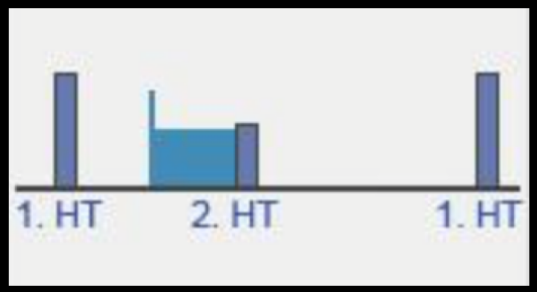

1: normal
2: normal
Holosystolisches Geräusch, bandförmig, fauchend
Ausstrahlung in Axilla, v. a. in Linksseitenlage
3: häufig vorhanden
MKP: systolischer Click und daran anschliessend MI

Palpation:
Herz: Hebender lateralisierter Herzspitzenstoss, eventuell systolisches Schwirren
Puls: Häufig unregelmässig wegen VHF

Arterieller Blutdruck:
Normale Amplitude

EKG:
Sinusrhythmus (VHF); Linkslage; Linkshypertrophie; Repolarisationsstörung

Mitralinsuffizienz

Untersuchung von Patienten mit MI

Auskultationsort	Schematische phonokardiografische Darstellung	Key point
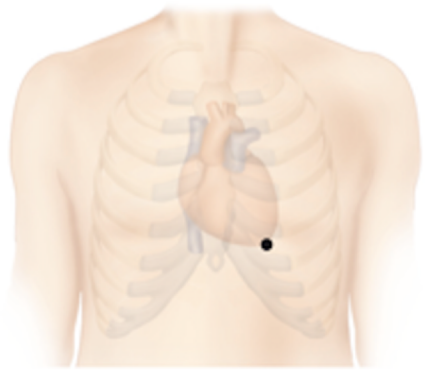 p.m.: Herzspitze	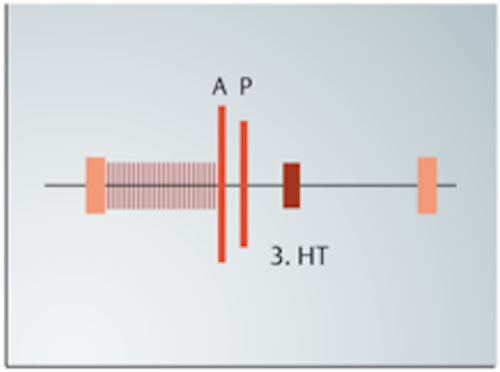	Herztöne: 1. HT leise oder fehlend, 2. HT breit gespalten Extratöne: 3. HT Herzgeräusche: hochfrequentes, holosystolisches, bandförmiges Geräusch

Mitralklappe: Prolaps

Formen der Mitralinsuffizienz

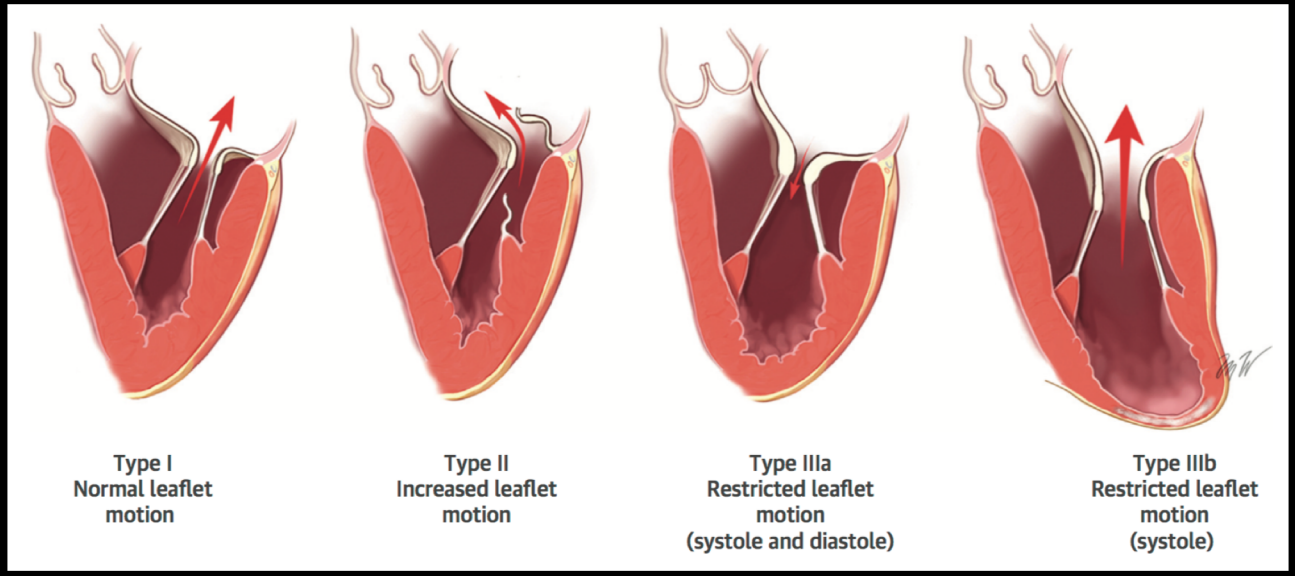

	Primary Mitral Regurgitation	Secondary Mitral Regurgitation
Prognosis	Primarily dependent on the severity of mitral regurgitation and secondarily on left and right ventricular function and pulmonary pressures	Primarily dependent on the degree of underlying left ventricular dysfunction and secondarily on the severity of mitral regurgitation
Principal management strategy (standard of care)	Mitral valve surgery when severe (repair preferred to replacement); MitraClip may be considered in patients at prohibitive surgical risk with appropriate anatomy	GDMT for heart failure ± cardiac resynchronization therapy ± coronary revascularization when indicated; mitral valve surgery (repair or replacement) is not common clinical practice but may be considered in selected cases

Stone G. et al. J Am Coll Cardiol 2015;66:278-307

Primäre Mitralinsuffizienz

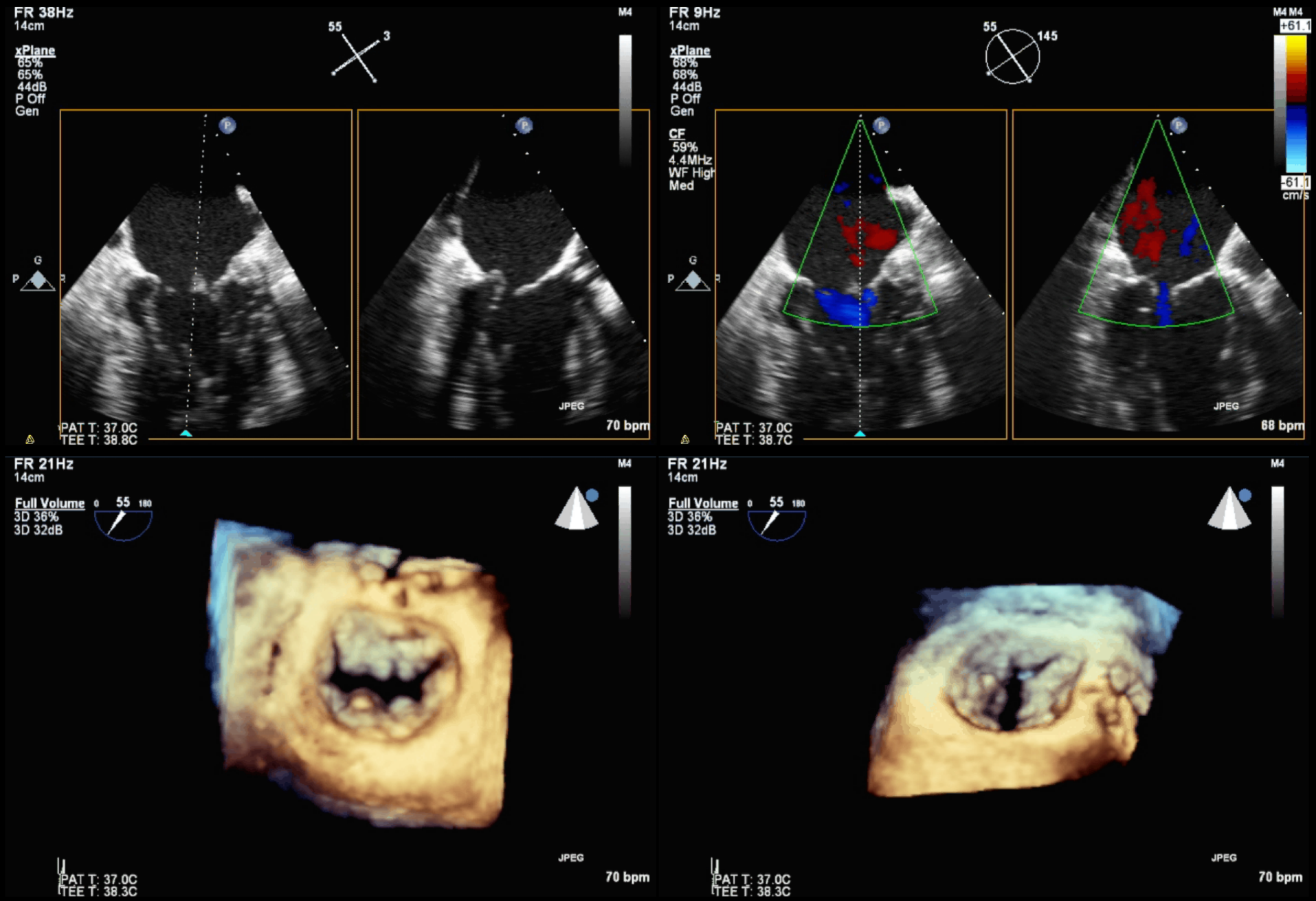

Quantifizierung der Mitralinsuffizienz

	MR severity*			
	Mild	Moderate		Severe
Structural				
MV morphology	**None or mild leaflet abnormality** (e.g., mild thickening, calcifications or prolapse, mild tenting)	Moderate leaflet abnormality or moderate tenting		**Severe valve lesions** (primary: flail leaflet, ruptured papillary muscle, severe retraction, large perforation; secondary: severe tenting, poor leaflet coaptation)
LV and LA size†	Usually normal	Normal or mild dilated		Dilated‡
Qualitative Doppler				
Color flow jet area§	**Small, central, narrow, often brief**	Variable		Large central jet (>50% of LA) or eccentric wall-impinging jet of variable size
Flow convergence‖	**Not visible, transient or small**	Intermediate in size and duration		**Large throughout systole**
CWD jet	Faint/partial/parabolic	Dense but partial or parabolic		Holosystolic/dense/**triangular**
Semiquantitative				
VCW (cm)	<0.3	Intermediate		≥0.7 (>0.8 for biplane)¶
Pulmonary vein flow#	**Systolic dominance** (may be blunted in LV dysfunction or AF)	Normal or systolic blunting#		Minimal to no systolic flow/ **systolic flow reversal**
Mitral inflow**	**A-wave dominant**	Variable		E-wave dominant (>1.2 m/sec)
Quantitative††,‡‡				
EROA, 2D PISA (cm^2)	<0.20	0.20-0.29	0.30-0.39	≥0.40 (may be lower in secondary MR with elliptical ROA)
RVol (mL)	<30	30-44	45-59††	≥ 60 (may be lower in low flow conditions)
RF (%)	< 30	30-39	40-49	≥50

Zoghby et al. J Am Soc Echocardiogr 2017

Prognose der schweren Mitralinsuffizienz

1-Jahres-Ueberleben von symptomatischen Patienten

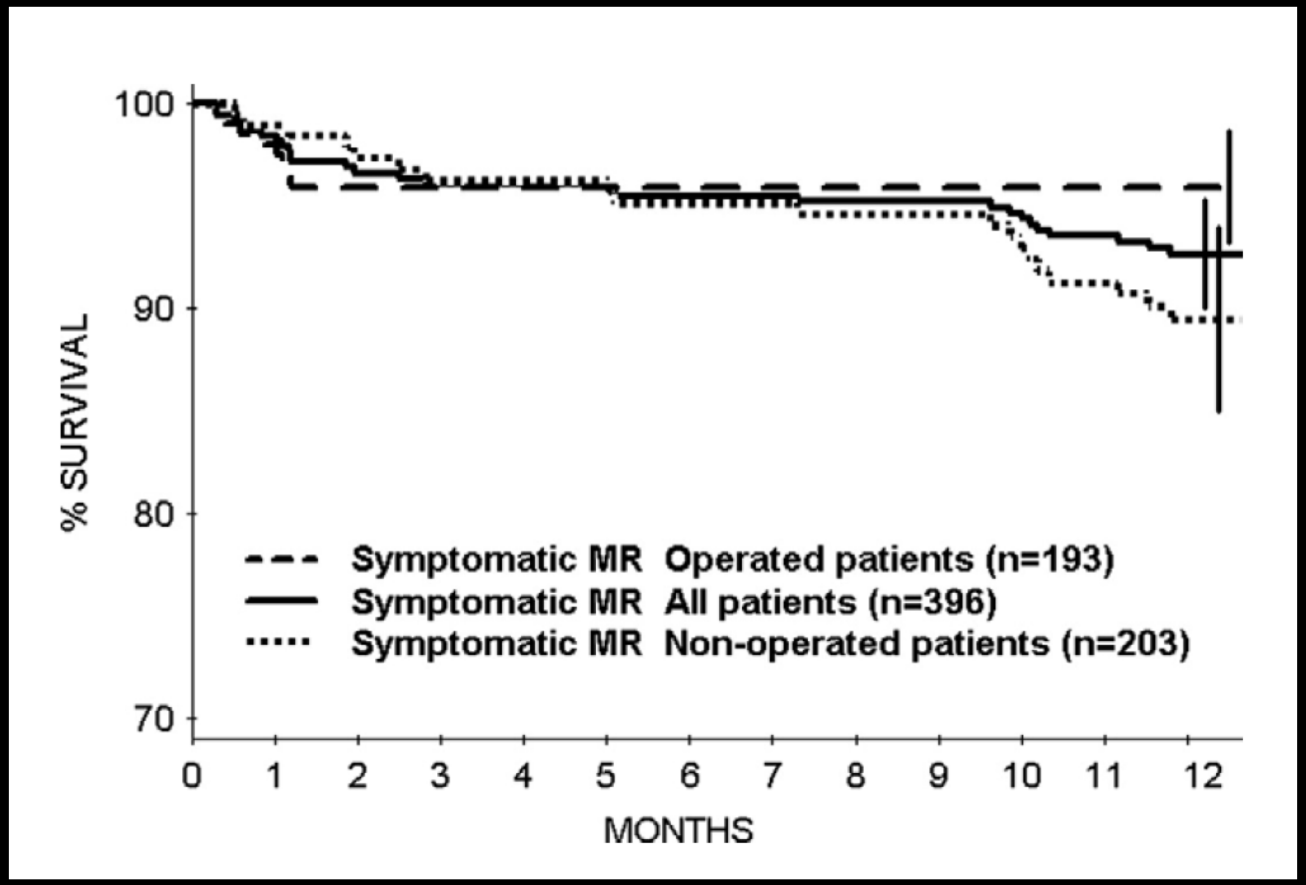

90% 1-Jahres-Ueberleben (schwer, symptomatisch, keine Intervention)

Iung et al. Curr Probl Cardiol 2007;32:609-661

Therapie der primären schweren Mitralinsuffizienz

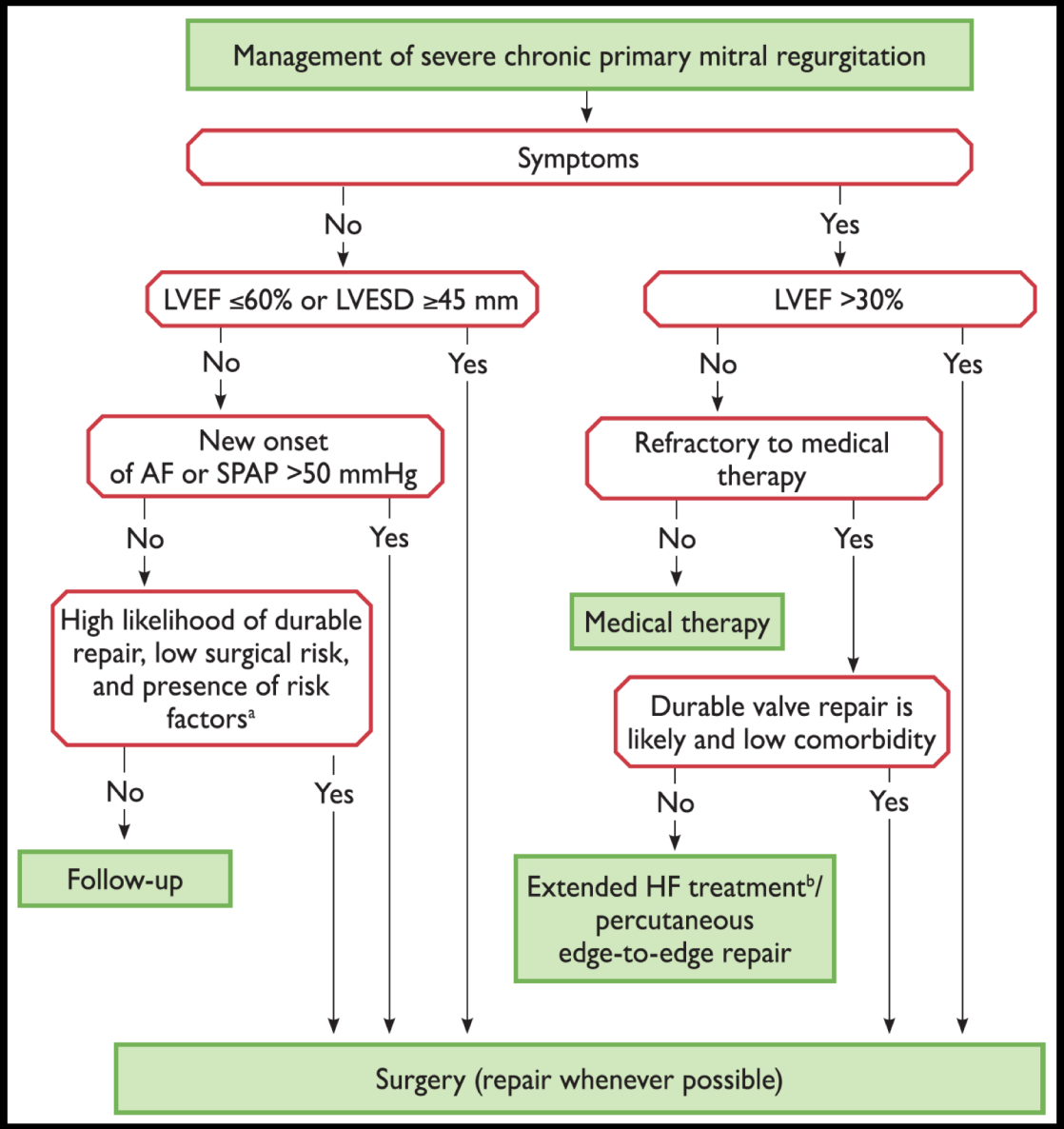

Baumgartner H. et al. Eur Heart J 2017;38:2739-2786

Sekundäre Mitralinsuffizienz

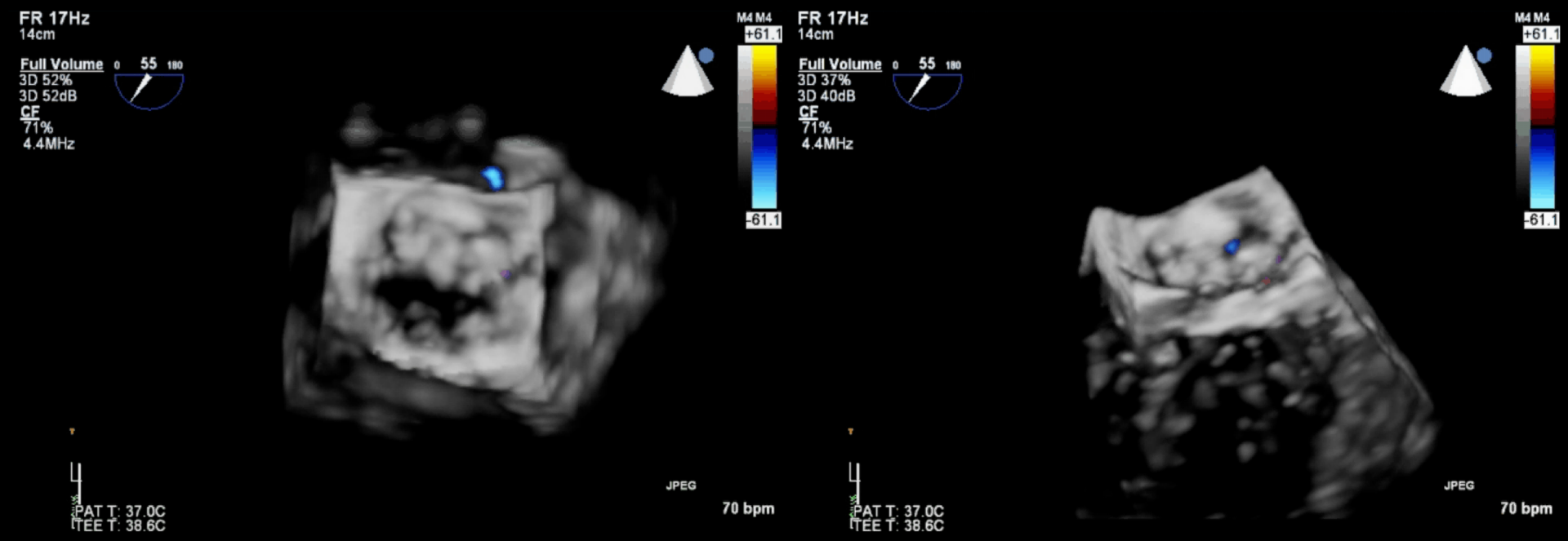

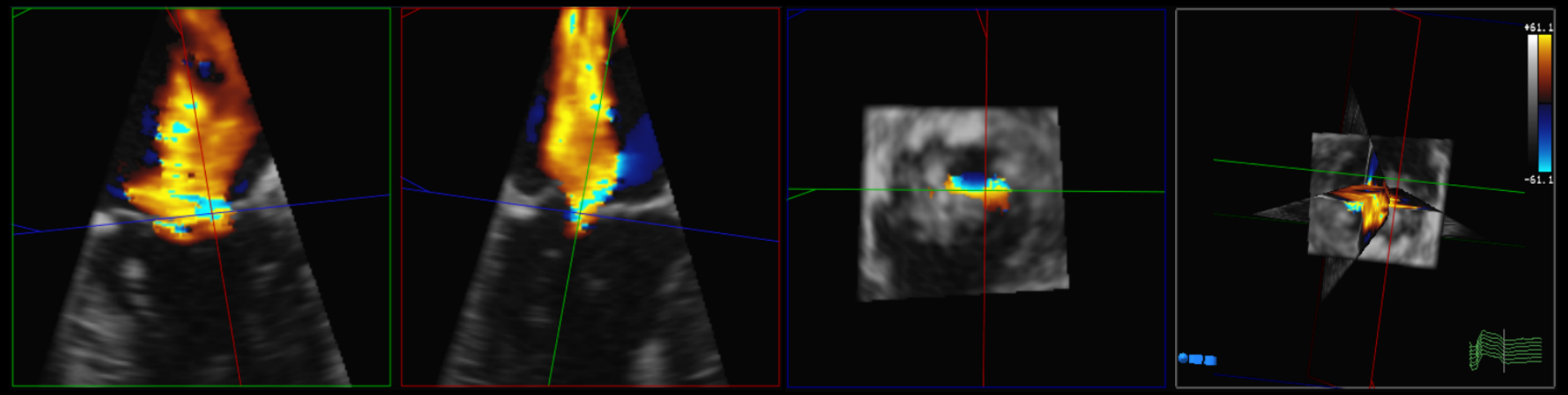

Therapie der sekundären schweren Mitralinsuffizienz

Recommendations	Class[b]	Level[c]
Surgery is indicated in patients with severe secondary mitral regurgitation undergoing CABG and LVEF >30%.	I	C
Surgery should be considered in symptomatic patients with severe secondary mitral regurgitation, LVEF <30% but with an option for revascularization and evidence of myocardial viability.	IIa	C
When revascularization is not indicated, surgery may be considered in patients with severe secondary mitral regurgitation and LVEF >30% who remain symptomatic despite optimal medical management (including CRT if indicated) and have a low surgical risk.	IIb	C
When revascularization is not indicated and surgical risk is not low, a percutaneous edge-to-edge procedure may be considered in patients with severe secondary mitral regurgitation and LVEF >30% who remain symptomatic despite optimal medical management (including CRT if indicated) and who have a suitable valve morphology by echocardiography, avoiding futility.	IIb	C
In patients with severe secondary mitral regurgitation and LVEF <30% who remain symptomatic despite optimal medical management (including CRT if indicated) and who have no option for revascularization, the Heart Team may consider a percutaneous edge-to-edge procedure or valve surgery after careful evaluation for a ventricular assist device or heart transplant according to individual patient characteristics.	IIb	C

No conclusive evidence for survival benefit after mitral valve intervention

Mitral valve intervention recommended when there is an indication for CABG

Mitral valve intervention without CABG can be considered when the patient is symptomatic despite optimal medical therapy and CRT

MitraClip can be considered in patients at high surgical risk

Baumgartner H. et al. Eur Heart J 2017;38:2739-2786

Mitralinsuffizienz und konventionelle Chirurgie

Table 1 | MV lesions differentiated by complexity* and surgical requirements for MV repair

	Simple lesions	Complex lesions	Lesions at high-risk of unsuccessful repair
Type of lesion	Posterior leaflet prolapse or flail (isolated mid-scallop involvement [P2], with or without redundant tissue [leaflet height ≥15 mm]) Annular dilation Leaflet perforation	Complex posterior leaflet lesions Anterior prolapse or flail Bileaflet prolapse or flail Commissural prolapse or flail Combined lesions Deviant anatomy	Prolapse and extensive annular calcification Prolapse with hypoplasia of opposite leaflet Extreme fibroelastic deficiency Post-endocarditis extensive destruction Rheumatic disease
Probability of successful and durable repair	High	Depends on experience of the surgical team	Low
Surgical techniques	Quadrangular or triangular resection (including sliding plasty according to leaflet height) Annuloplasty Patch or direct suture	Artificial chordae Chordal transposition Edge-to-edge technique	Very technically demanding techniques (including artificial chordae, leaflet enlargement, and annular decalcification)
Necessary expertise of surgical team	Low	High	Very high

*Judged by echocardiography. Abbreviation: MV, mitral valve.

De Bonis et al. Nat Rev Cardiol 2012;9:133-146

Mitralinsuffizienz und perkutane Rekonstruktion

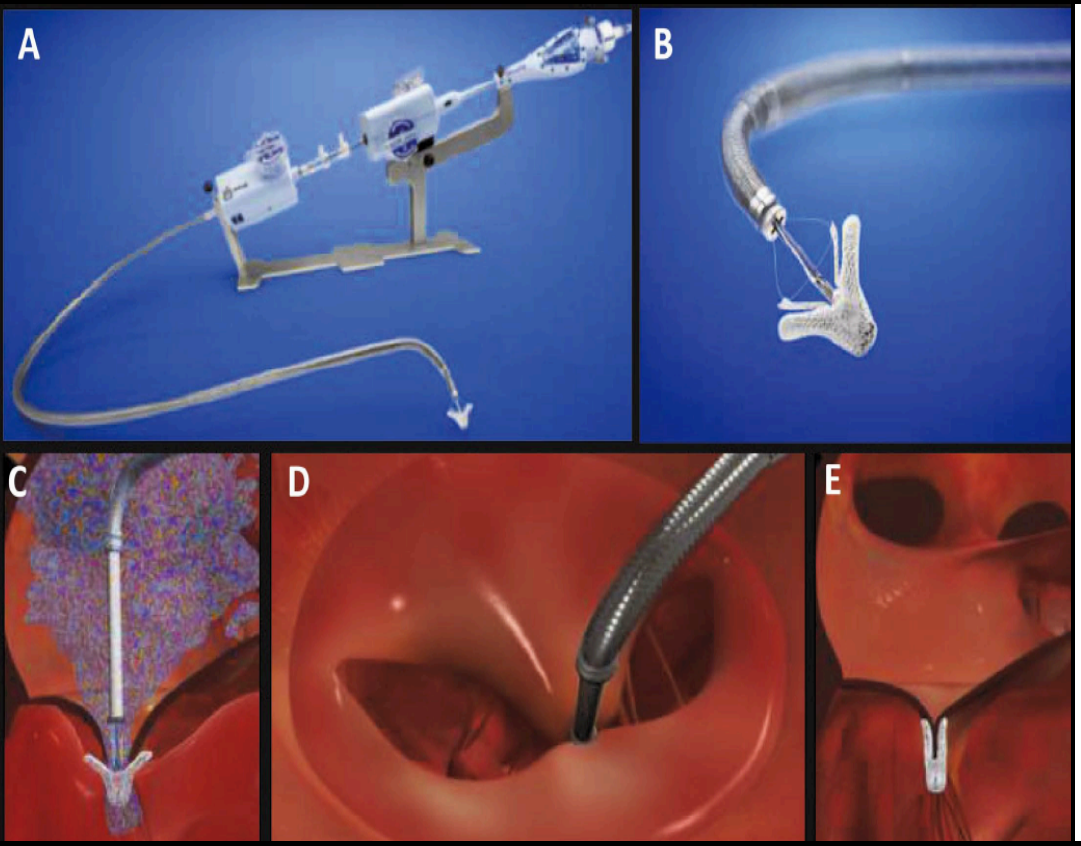

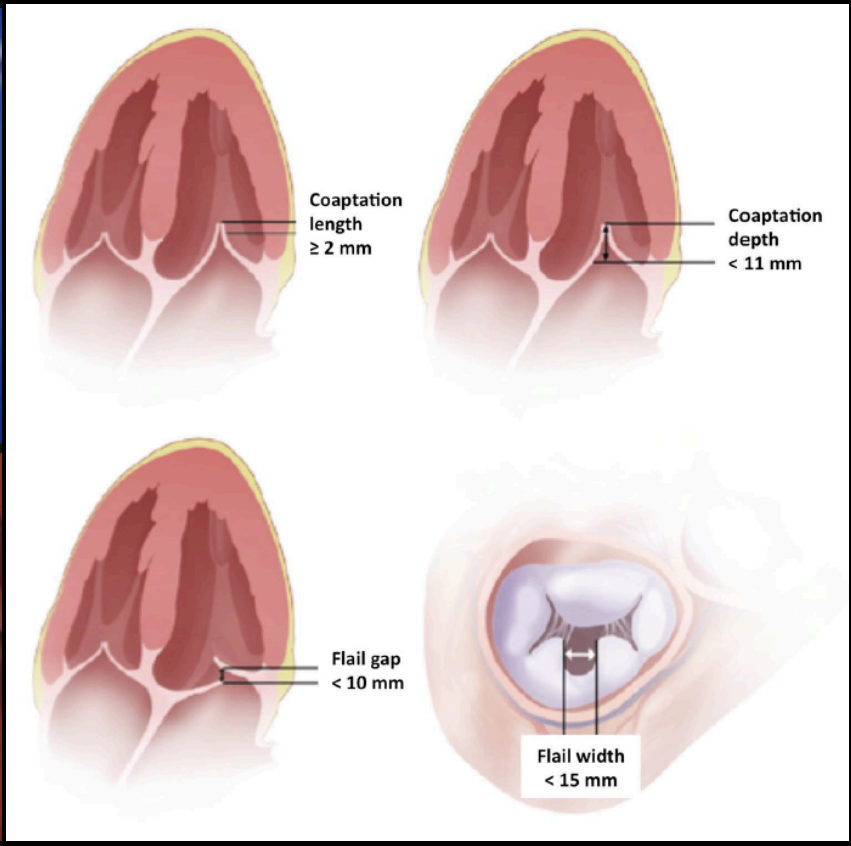

De Bonis et al. Nat Rev Cardiol 2012;9:133-146

Mitralinsuffizienz und medikamentöse Therapie

- Betablocker: keine Daten
- Diuretika, Nitrate: kontroverse Daten
  Ausgenommen: akute Mitralinsuffizienz
- Arterielle Hypertonie behandeln
- Gegebenenfalls Herzinsuffizienz behandeln
- Antikoagulation:
  - bei VHF und bei Thrombus im LA
  - für 3 Monate nach MKR